Differential Stroke Pattern among Childhood and Adult Onset Moyamoya Disease (MMD)

Dr. A T M HASIBUL HASAN

MCPS MD (Neurology)

Registrar (Clinical Neurology)

National Institute of Neurosciences & Hospital

Scenario-1

- A 12 yr old boy presented with recurrent episode of weakness of right side of the body along with difficulty in naming of known objects.

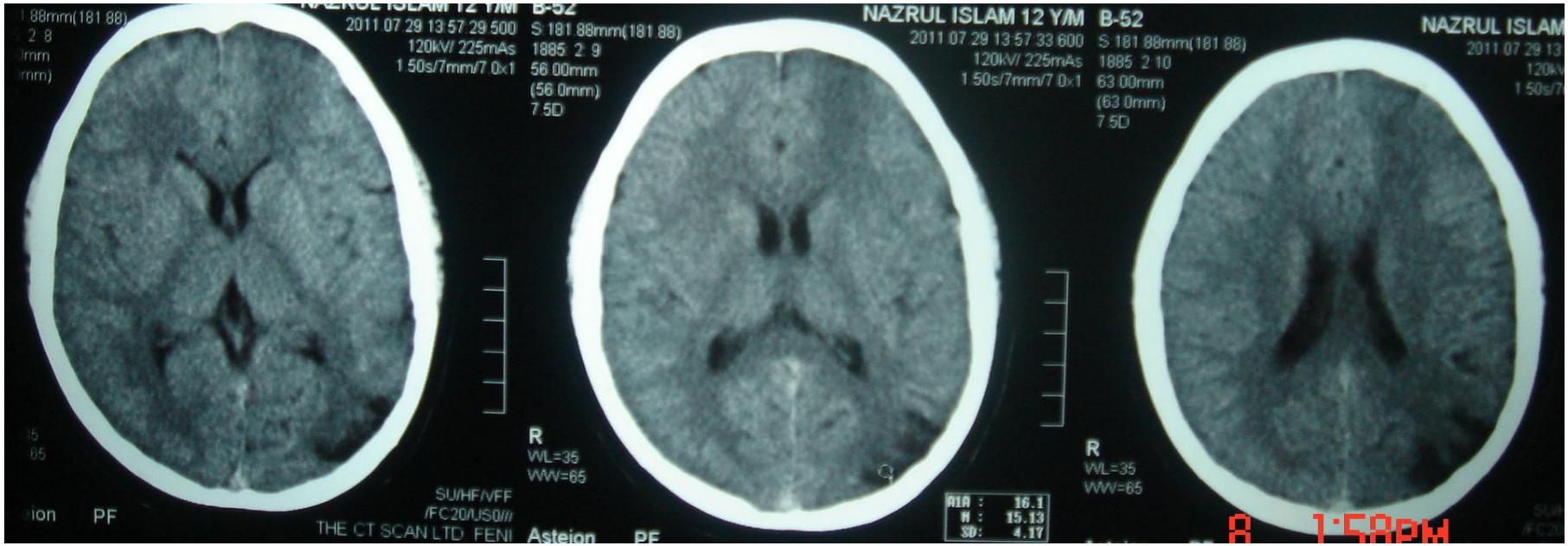
NAZRUL ISLAM 12 Y/M B-52
2011 07 29 13 57 29 500
120kV/ 225mAs
1 50s/7mm/7 0x1
S 181 88mm(181 88)
1885 2 9
56 00mm
(56 0mm)
7 5D
R
WL=35
WW=65
THE CT SCAN LTD FENI
Asteion PF
NAZRUL ISLAM 12 Y/M B-52
2011 07 29 13 57 33 600
120kV/ 225mAs
1 50s/7mm/7 0x1
S 181 88mm(181 88)
1885 2 10
63 00mm
(63 0mm)
7 5D
AIA : 16.1
M : 15.13
SD: 4.17
NAZRUL ISLAM
2011 07 29 13
120kV
1 50s/7
R
WL=35
WW=65
8 1:58PM

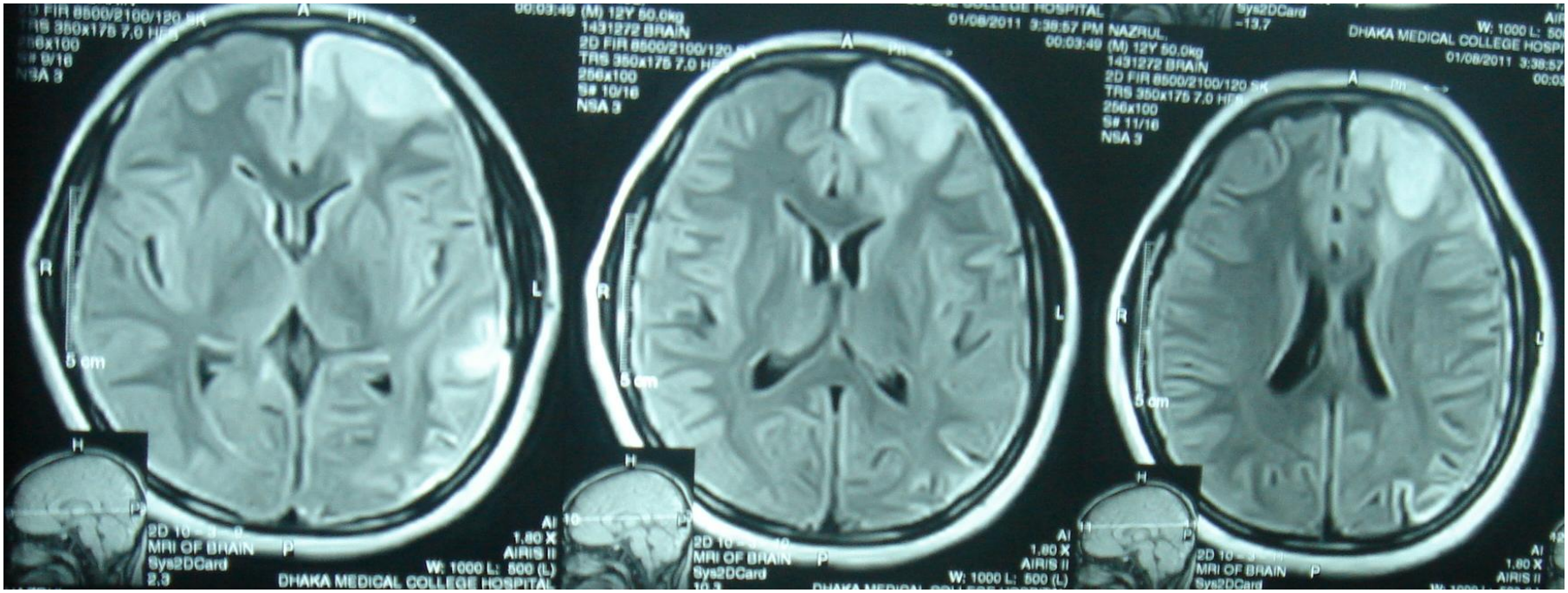
01/08/2011 9:38:57 PM NAZRUL
00:03:49 (M) 12Y 50.0kg
1431272 BRAIN
2D FIR 8500/2100/120 SR
TRS 350x175 7.0 HFS
256x100
S# 11/16
NSA 3
DHAKA MEDICAL COLLEGE HOSPITAL
01/08/2011 9:38:57
W: 1000 L: 500 (L)
MRI OF BRAIN
Sys2DCard
AI
1.80 X
AIRIS II
5 cm

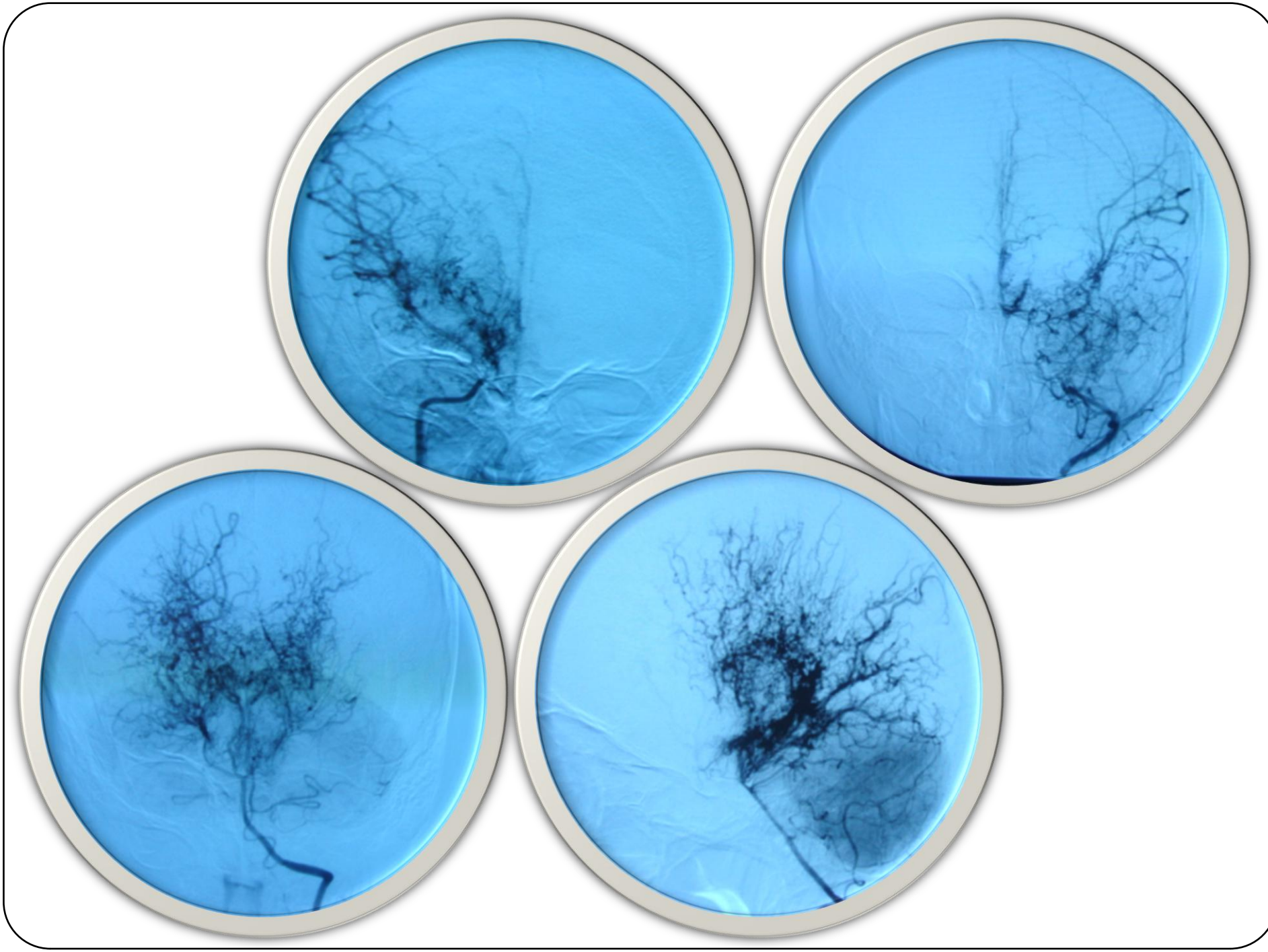

Scenario-2

- A 35 yr old normotensive lady presented with sudden severe headache, vomiting and loss of consciousness.

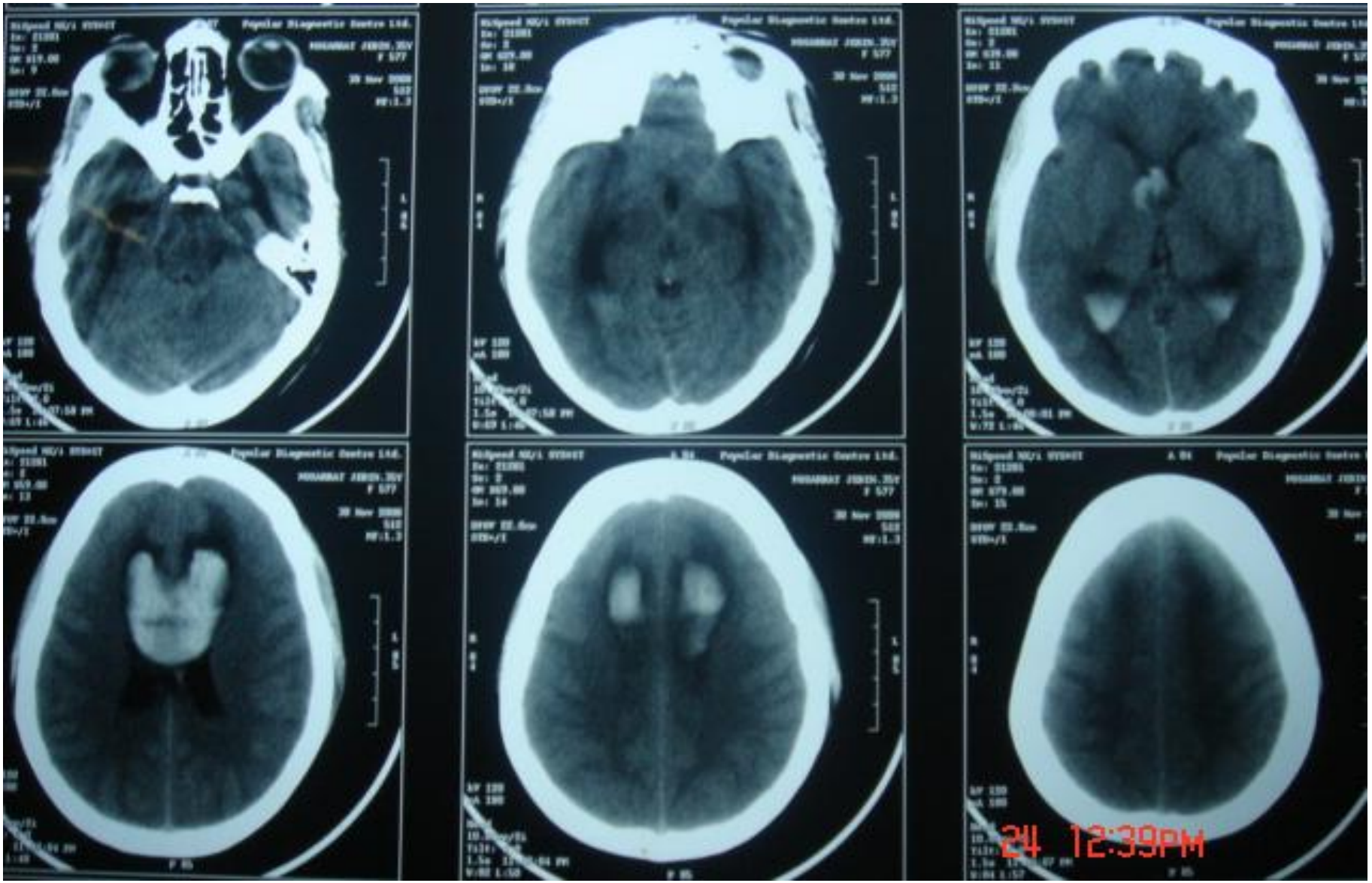
Popular Diagnostic Centre Ltd.
24 12:39PM

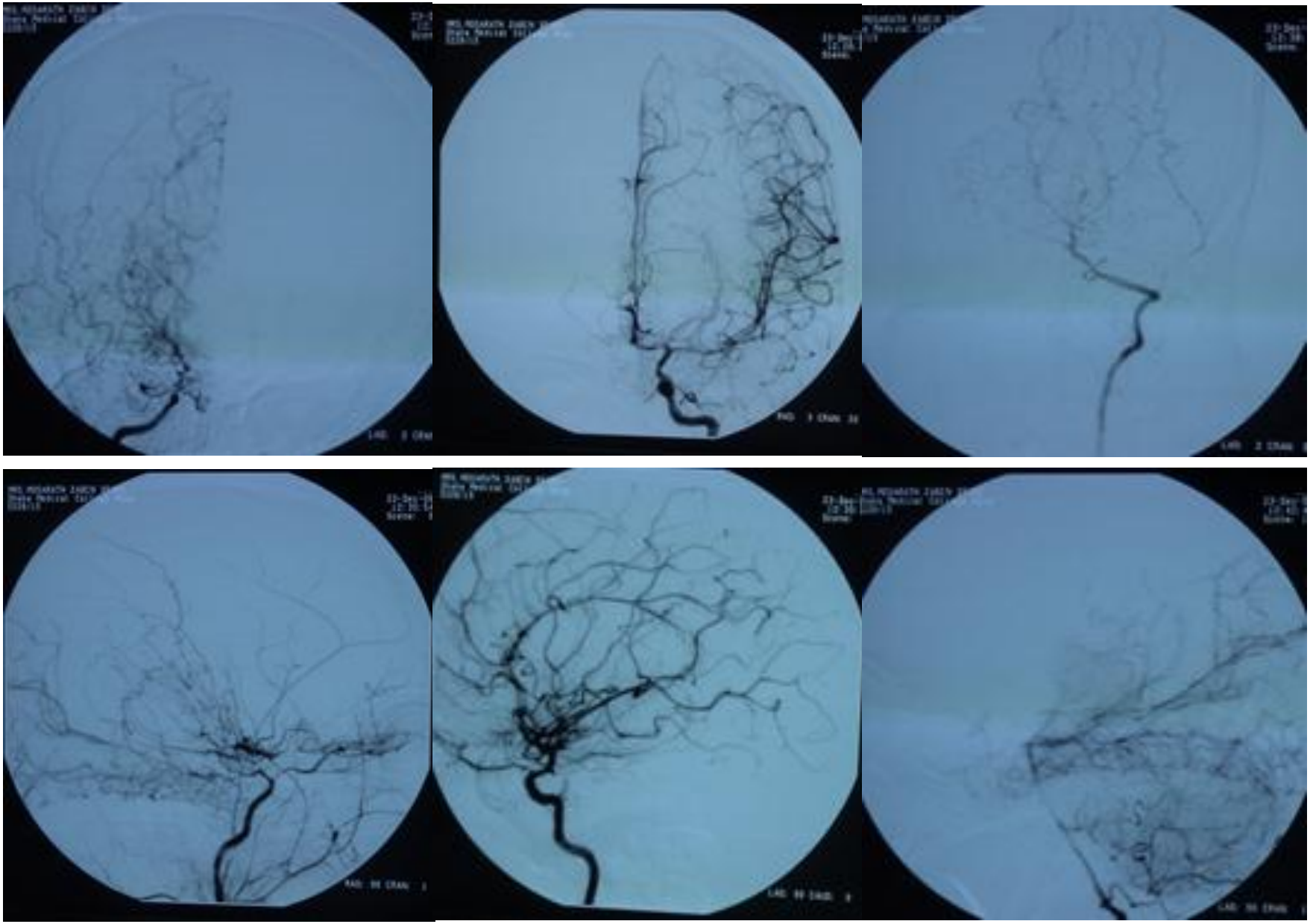

Introduction

- MOYAMOYA, a Japanese word meaning "something hazy like a puff of cigarette smoke drifting in the air,‘’
- It is a descriptive term that is applied to a peculiar angiographic picture consisting of abnormal net-like vessels at the base of the brain. (Takeuchi and Shimizu 1957)

Introduction (Cont.)

- For several decades since its discovery in 1957, MMD has been considered to be mainly confined to certain ethnic groups, particularly among the Japanese.

- Now-a-days, MMD is increasingly diagnosed throughout the world.

- MMD was largely unknown in Bangladesh before the introduction of digital subtraction angiography (DSA) in this country.

Introduction (Cont.)

- Clinically, MMD exhibits diverse symptoms and children most commonly present with ischemic deficit while the adult develop intracerebral hemorrhage.

- However, symptom cross over between these two age groups is also not uncommon.

Introduction (Cont.)

- Understanding the relation between the age of onset and characteristics stroke types may be helpful in planning the strategy of treatment in this group of patients, especially, in resource poor settings.

- So, age of onset of MMD was compared with the stroke subtypes to identify whether there is any association or not in our settings.

Research methodology

Study Design:

Observational study.

Place of Study:

- Department of Neurology, Dhaka Medical College Hospital;
- Department of Neurology, Bangabandhu Sheikh Mujib Medical University
- Department of Interventional Neurology, National Institute of Neurosciences and Hospital

Research methodology(cont'd)

Study Period:

From July, 2007 to June, 2016

Study population

Patients with MMD.

Research methodology (cont'd)

Sample size:

Fifty (50)

Sampling technique:

Purposive sampling.

Selection criteria:

Inclusion criteria:

1) Age: >5 years.
2) CT and/ MRI proven stroke.
3) DSA within one month of stroke to confirm the MMD.

Selection criteria:(cont'd)

Exclusion criteria:

1) Patients with suspected or probable MMD.
2) Patients with moyamoya syndrome.
3) DSA performed after one month of stroke.
4) Patients who underwent surgical procedure for MMD.

Operational Definition

Moyamoya disease:

- Moyamoya vasculopathy without any known vascular risk factors (hypertension, diabetes and smoking).

- Must have bilateral disease

Operational Definition(cont'd)

- Childhood MMD (C-MMD) : ≤20 years of age at onset
- Adult onset MMD (A-MMD): >20 years of age at onset

Operational Definition(cont'd)

Diagnostic Criteria (RCMJ criteria):

A. Cerebral angiography is indispensable for the diagnosis and the following findings should be present -

1. Stenosis or occlusion at the terminal portion of the internal carotid artery and/or at the proximal portion of the anterior and/or the middle cerebral arteries;

2. Abnormal vascular networks in the vicinity of the occlusive or stenotic lesions in the arterial phase; and

3. Bilaterally.

.

Operational Definition(cont'd)

B. When MRI and MRA clearly demonstrate all the subsequently described findings-

1. Stenosis or occlusion at the terminal portion of the internal carotid artery and at the proximal portion of the anterior and middle cerebral arteries on MRA;

2. An abnormal vascular network in the basal ganglia on magnetic resonance angiography.

3. These findings should present bilaterally.

Operational Definition(cont'd)

C. Because the etiology of this disease is unknown, the following basic diseases or conditions should thus be eliminated:

1. Arteriosclerosis;
2. Autoimmune disease;
3. Meningitis;
4. Brain neoplasm;
5. Down syndrome;
6. Recklinghausen's disease;
7. Head trauma;
8. Irradiation to the head; and
9. Others.

Operational Definition(cont'd)

Diagnosis

As mentioned previously, the diagnostic criteria are classified as follows:

- Definite case: one that fulfills either (A) or (B) and (C).

  [In children, however, a case that fulfills (A) (1) and (2) or (B) (1) and (2) on one side and with remarkable stenosis at the terminal portion of the internal carotid artery on the opposite side is also included.]

- Probable case: one that fulfills (A) (1) and (2) or (B) (1) and (2) and (C) (unilateral involvement).

Operational Definition(cont'd)

To compare the angiographic characteristics between acute ischemic stroke and hemorrhagic stroke in adult MMD, the stroke were further subtyped into groups as follows:

1. **Large-artery infarct (LAI):** ACA infarct, anterior or posterior half of an MCA infarct and a PCA infarct.
2. **Hemodynamic infarct (HI):** Perforator infarct (PI); anterior watershed and posterior watershed infarct.
3. **Deep intracerebral hemorrhage (dICH):** Basal ganglia or thalamic hemorrhage.
4. **Lobar intracerebral hemorrhage (lICH):** Frontal, temporal, parietal or occipital lobe hemorrhage.
5. Hemorrhage within the ventricle (IVH); and that within subarachnoid spaces and cisterns (SAH).

Data analysis:

- Data analysis was done with the help of Statistical Package for the Social Sciences (SPSS) version 19.0 software facilities.

- Appropriate statistical methods were applied for data analysis and comparison among different variables with 95% confidence interval (CI) and taking p value $\leq$ 0.05 as significant.

RESULTS

Table I: Distribution of patients by age at onset (n=50)

Age group (Years)	Frequency	Percentage
Child	35	70.0
Adult	15	30.0
Total	50	100.0
Mean (±SD)	16.56(±10.6) years	5-43 years

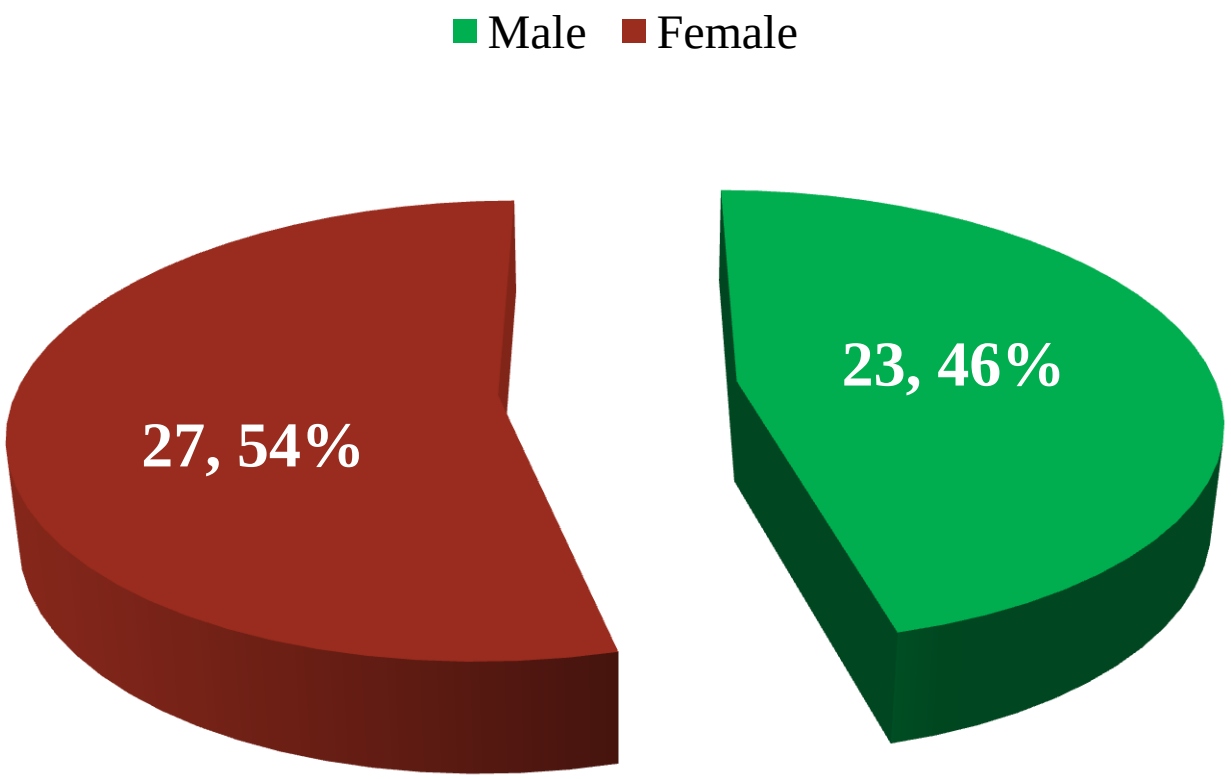

Figure-I : Sex distribution of the study patients (n=50))

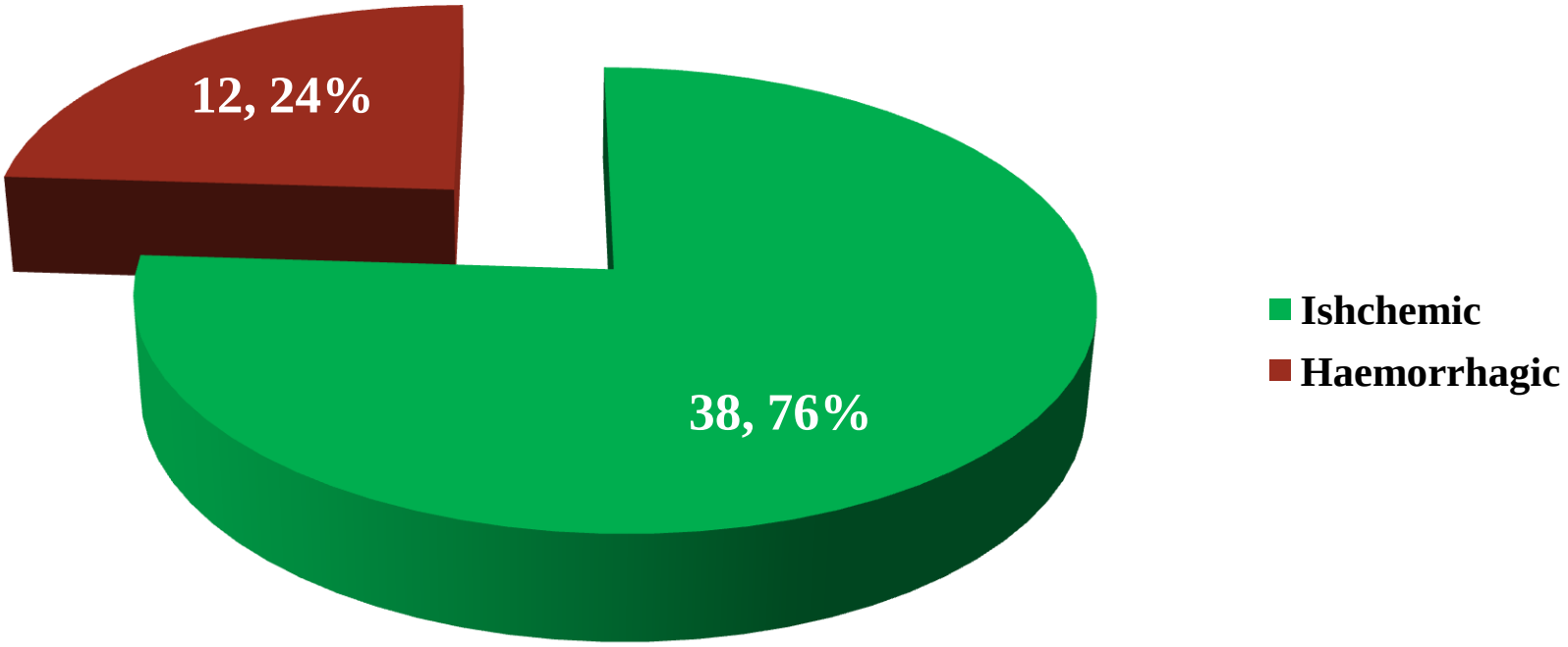

Figure -II: Distribution of the study patients by stroke types (n=50)

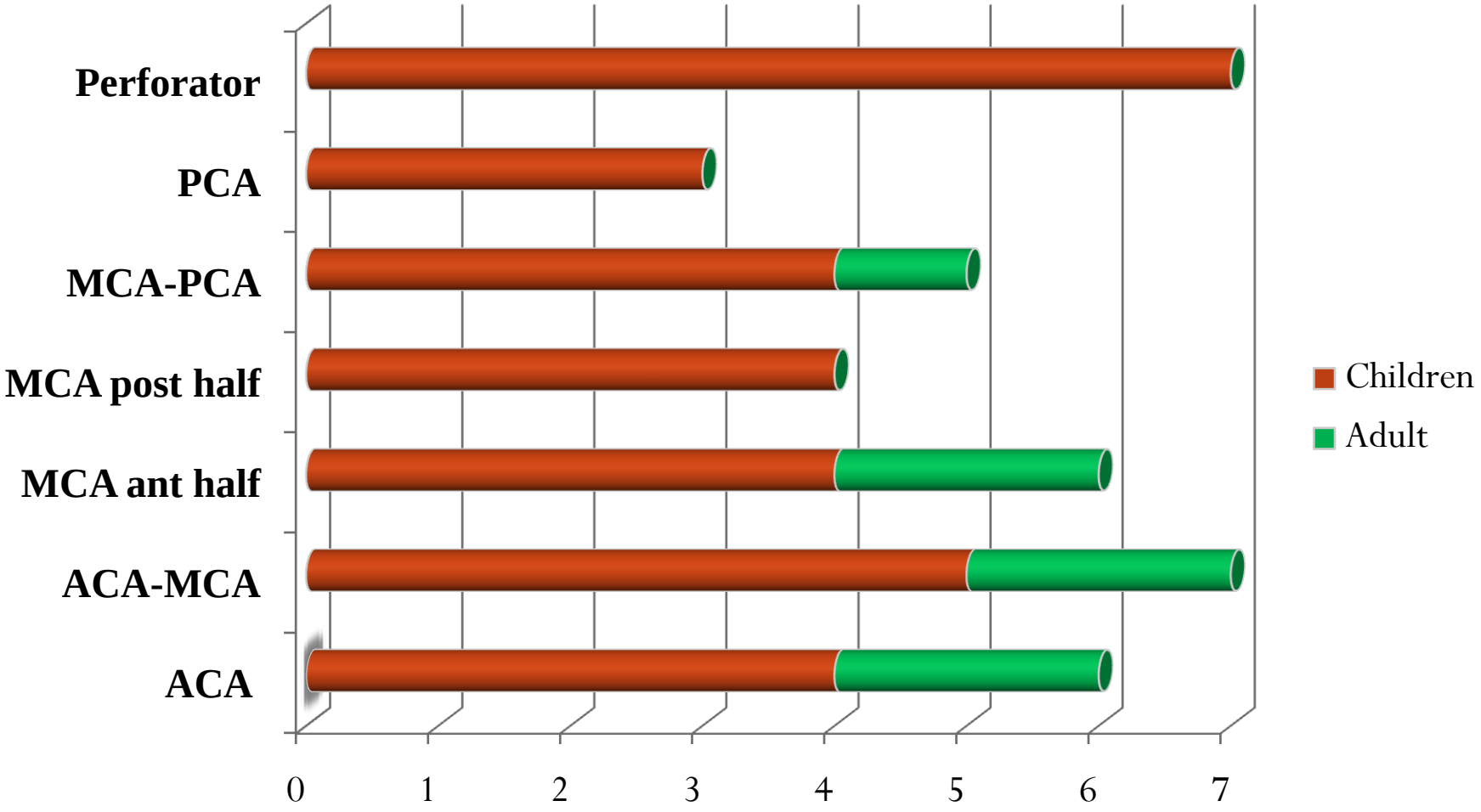

Figure-III: Ischemic stroke subtypes according to involved arterial territory among study patients (n=38)

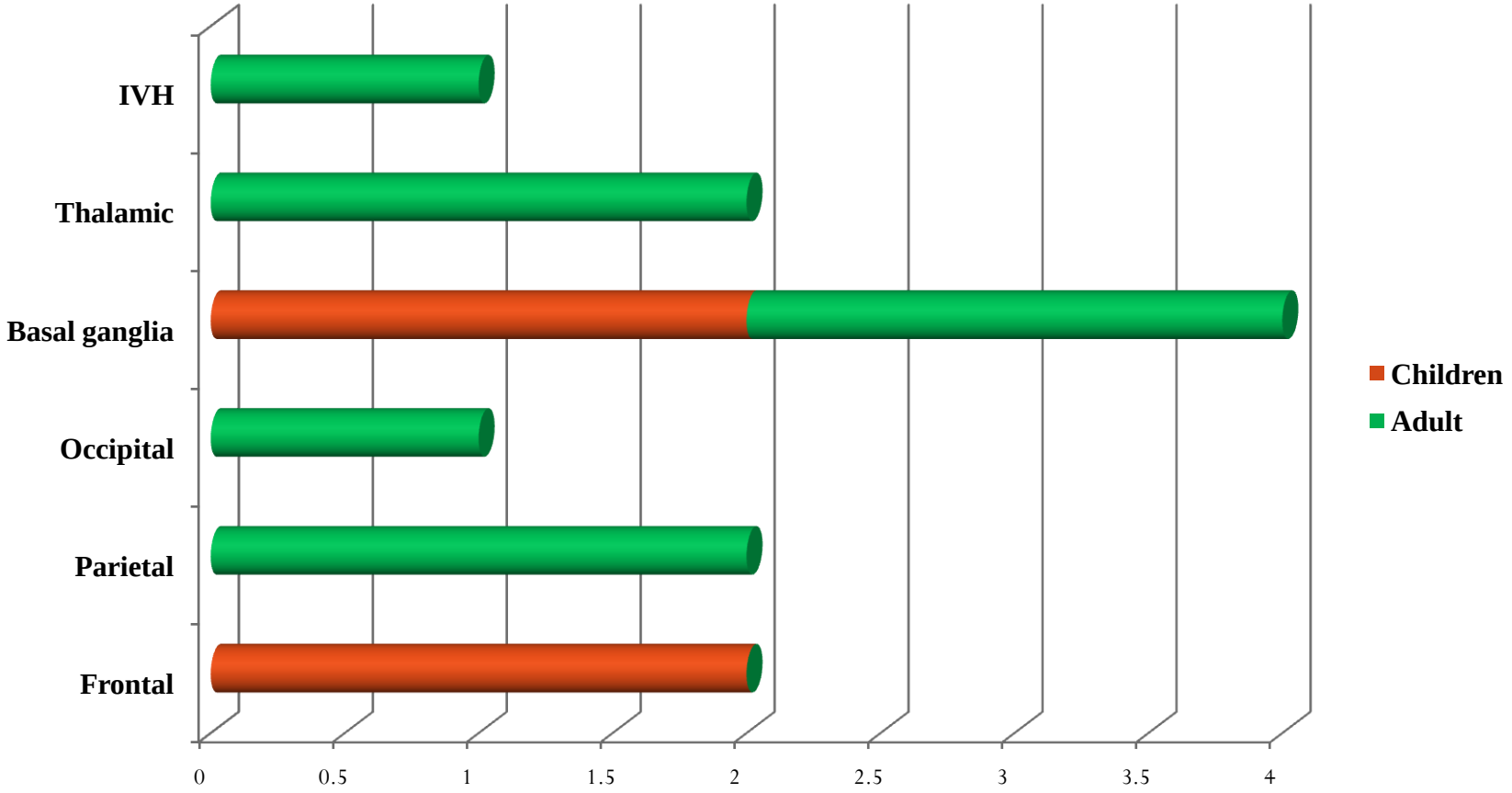

Figure-IV: Hemorrhagic stroke subtypes according to location of hematoma among study patients (n=12)

Table- II: Distribution of stroke types in different age groups (n=50)

Age group (Years)	**Stroke types** (Number)		***p* value**
	Ischemic	**Hemorrhagic**	
Children	31	4	0.003
Adult	7	8	
Total	38	12	

Table- III: Distribution of stroke subtypes in different age groups (n=50)

Age group (Years)	**Stroke subtypes** (Number)						***p* value**
	LAI	**HI**	**dICH**	**lICH**	**IVH**	**SAH**	
Children	14	17	3	1	0	0	0.01
Adult	3	4	3	4	1	0	
Total	17	21	6	5	1	0	

Discussion:

- This was a hospital based cross sectional type of observational study involving 35 children and 15 adult patients.

- The age and sex distribution of our study patients were similar to the report of Wakai K et al and Ikezaki K et al where majority of the study were younger with a slight female preponderance (Wakai K 1997, Ikezaki k 1997).

Discussion (cont'd)

- Similar to the reports of other studies, majority of the patients (76%) had ischemic stroke while 24% had hemorrhagic stroke (Ikezaki K 1997, Chiu D 1998 and Han C 2012). .

- The distribution of stroke subtypes among different age groups were also similar to the reports from other Asian countries, especially the Japanese (Baba T 2008, Ikezaki K 1997, Miao W 2010).

Discussion (cont'd)

- The age specific difference in presentation of stroke subtypes among C-MMD and A-MMD was similar to the report of Houkin K et al, where all pediatric moyamoya patients (35 patients) had ischemic (nonhemorrhagic) onset, whereas 19 cases (56%) of adult moyamoya patients had hemorrhagic onset (Houkin K 1996).

LIMITATIONS

- This is a hospital based study which may not reflect the whole scenario of the country.
- Sample size was small.
- This is an observational study.
- Patients were selected from three centers in Dhaka city which may pose some inter observer variability in reporting the angiographic stage of MMD.

Conclusion

- C-MMD patients present mostly with ischemic stroke subtypes whereas hemorrhagic stroke subtypes are more frequent among A-MMD.

References:

- Baba T, Houkin K, Kuroda S, 2008, 'Novel epidemiological features of moyamoya disease'. *Journal of Neurology Neurosurgery & Psychiatry*, vol. 79, pp. 900-904.
- Chiu D, Shedden P, Bratina P, 1998, 'Clinical feature of moyamoya disease in the United States'. *Stroke*, vol. 29, pp. 1347-51.
- Han C, Chen J, Gao S, 2012, 'Moyamoya disease in Asia'. *Neurology Asia*, vol. 17, No 3, pp. 175 – 181.
- Houkin K, Yoshimoto T, Kuroda S, 1996, 'Angiographic analysis of moyamoya disease: how does moyamoya disease progress?' *Neurologia Medico- Chirurgica*, vol. 36, pp. 783-88.
- Ikezaki K, Han DH, Kawano T, Kinukawa N, Fukui M, 1997, 'A Clinical Comparison of Definite Moyamoya Disease between South Korea and Japan'. *Stroke, vol.* 28, pp. 2513-17.
- Kuriyama S, Kusaka Y, Fujimura M, Wakai K, Tamakoshi A, Hashimoto S, 2008, 'Prevalence and clinicoepidemiological features of moyamoya disease in Japan: findings from a nationwide epidemiological survey'. *Stroke*, vol. 39, pp. 42–47.
- Miao W, Zhao PL, Zhang YS, 2010, 'Epidemiological and clinical features of Moyamoya disease in Nanjing, China'. *Clinical Neurology & Neurosurgery*, vol. 112, No 3, pp. 199-203.
- Nagaraja D, Verma A, Taly AB, Kumar MV, Jayakumar PN, 1994, 'Cerebrovascular disease in children'. *Acta Neurologica Scandinavica*, vol. 90, pp. 251-5.
- Takeuchi K, Shimizu K, 1957, 'Hypoplasia of the bilateral internal carotid arteries' . *No To Shinkei (Brain and Nerve Journal)*, vol. 9, pp. 37–43.
- Wakai K, Tamakoshi A, Ikezaki K, 1997, 'Epidemiological features of moyamoya disease in Japan: findings from a nationwide survey'. *Clinical Neurology & Neurosurgery*, vol. 99, No 2, Suppl S1-S5.

thank you
danke
謝謝
ngiyabonga
teşekkür ederim
gracias
merci
obrigado
dziękuję
bedankt
go raibh maith agat
mochchakkeram
sukriya
kop khun krap
terima kasih
grazie
arigatô
dakujem
takk
taiku
tapadh leat
спасибо
рахмат
Баярлалаа
mersi
barka
welalin
tack
spas
dank je
misaotra
matondo
paldies
grazzi
mahalo
vinaka
blagodaram
спасибі
faafetai lava
kiitos
dankie
dhanyavad
nanni
nandri
bayarlalaa
gracie
hvala
mauruuru
köszönöm
enkosi
akun
dankon
aciu
хвала
asante
manana
obrigada
tenki
murakoze
chokrane
djiere dieuf
tau
дякую
mamnun
chnorakaloutioun
gratias ago
gràcies
sulpáy
sobodi
dèkuji
sagolun
mèsi
didi madloba
najis tuke
kam sah hamnida
rahmat
ありがとう
tanemirt
rahmet
diolch
dhanyavadagalu
shukriya
merce
мерси
trugarez
xièxie
감사합니다
ευχαριστώ