WELCOME

A 35 year old male with two episodes of unconsciousness and recurrent limb weakness

Dr. Farjana Ahmed
Intern
DMCH

Salient Feature

Our patient Mr. J.H, 35 years old, muslim, non diabetic, non-smoker, non-alcoholic, normotensive, non-ashmatic hailing from Chatkhil, Noakhali ,got admitted into the DMCH on 15th December 2014 with the complaints of;

1. **Two episodes of unconsciousness within 14 months**
2. **Recurrent limb weakness over the last 11 months**
3. **Blurring of vision of both eyes for 11 months**

According to the statement of the patient, he was reasonably well about 14 months back, then on one morning while staying in Dubai, he was found **unconscious** by his colleagues and immediately taken to the nearby hospital where he was treated accordingly and discharged 7 days later without having any neurological deficit , though he could not show the documents of treatment as because he lost it in Dubai.

On query, prior to the illness, there was no history of fever, headache, convulsion, visual problems, ear problems, vomiting, weakness, trauma, vaccination or any loss of sphincter control.

After 4 weeks of recovery from unconsciousness he had decided to return to Bangladesh and henceforth was reasonably well for about 3 months.

Then again he developed **unconsciousness** associated with **generalised convulsion** and **weakness of the right half of the body** along with progressive **deterioration of visions of both eyes.**

For this reason, he was admitted into a Tertiary Hospital and was diagnosed as a case of sequale of encephalitis, secondary generalised seizure with chorioretinitis of right eye and tractional retinal band of left eye.

During this time at the Tertiary Hospital, he was treated with Inj. Ceftriaxone, Inj. Acyclovir, Inj. Dexamethasone, Inj. Omeprazole, Tab. Sodium Valporate and Vitrectomy of the left eye after consultation from an Opthalmologist.

He had regained his consciousness after 3 days. 20 days later, he was discharged without any residual weakness, though he had mild persistent headache and visual problem of both eyes.

1 month after discharge from that Tertiary Hospital, the patient again developed **weakness of the right half of the body**, for which he got admitted into another Tertiary Hospital and was treated symptomatically and discharged after a month without any conclusive diagnosis though he obtained complete recovery from his weakness.

3 months of discharge from that Tertiary Hospital, he again suddenly developed **weakness of right lower limb** for which he got admitted to DMCH. On query he gave no history with any fever, unconsciousness, convulsion or bowel or bladder complaints.

Throughout the course of illness he never gave any history of fever, vaccination, trauma , pain and joint swelling, rash, oral ulcer, respiratory distress, history of any TB contact, any neuro-psychiatric symptoms, any extramarital sexual exposure, nor any other systemic symptoms. He has three sisters and three brothers, his father and one of his uncle had died from stroke.

General Examination

Examination	Findings
Appearance	Ill – looking
Body Built	Normal
Cooperation	Cooperative
Decubitus	On choice
Anemia	Absent
Jaundice	Absent
Oedema	Absent
Dehydration	Absent
Pulse	90 bpm
BP	120/80 mmHg
Temperature	99F
Respiratory Rate	18 bpm

Examination	Findings
Clubbing	Absent
Koilonychia	Absent
Leukonychia	Absent
Cyanosis	Absent
Palmer Erythema	Absent
Flapping tremor	Absent
Spider Naevi	Absent
Lymphadenopathy	Not palpable
Thyroid Gland	Not enlarged
JVP	Not engorged

Systemic Examination on Nervous System

1. **Higher psychic function including speech:** Normal

2. **Cranial nerves examination:**

   - Optic Nerve Examination : Fundoscopic finding of both eyes revealed retinopathy with pallor of disc (media was hazy), which were more prominent on the left side.
   - All other cranial nerves were intact.

3. Motor System

	UPPER LIMBS		LOWER LIMBS	
	Right limb	**Left limb**	**Right limb**	**Left limb**
POWER	5/5	5/5	**3/5**	5/5
TONE	**Increased**	**Increased**	**Increased**	**Increased**
BULK	Normal	Normal	Normal	Normal

REFLEXES						
Jerks	**Biceps**	**Triceps**	**Supinator**	**Knee**	**Ankle**	**Plantar**
Right	Exaggerated	Exaggerated	Exaggerated	Exaggerated	Exaggerated	Extensor
Left	Exaggerated	Exaggerated	Exaggerated	Exaggerated	Exaggerated	Extensor

Ankle Clonus	Present Bilaterally
Co-ordination of Movement	Normal in upper limbs; **Heel-shin test** could not be evaluated properly due to weakness.
Involuntary movements	Absent

4. Sensory System

	UPPER LIMBS		LOWER LIMBS	
	Right	**Left**	**Right**	**Left**
Pain & Temperature	Intact	Intact	Intact	Intact
Touch & pressure	Intact	Intact	Intact	Intact
Joint position	Intact	Intact	Intact	Intact
Vibration	Intact	Intact	Intact	Intact

Cerebellar function	Intact
Gait	Could not be evaluated properly due to weakness
Sign of meningeal irritation	Absent

Other Systemic Examinations

- **Respiratory System:** Revealed no abnormalities
- **CVS System:** Revealed no abnormalities
- **GIT System:** Revealed no abnormalities

Provisional Diagnosis

???

Recurrent Multiphasic Disseminated Encephalomyelitis

Differential Diagnosis

???

- Recurrent acute disseminated encephalomyelitis
- Multiple Sclerosis
- Devic’s Disease (Neuromyelitis Optica)
- Neurosyphilis

Investigation Profile

CBC with ESR & PBF on 19.12.2014

TEST	RESULT	REFERENCE
WBC (Total Count)	7500/ cmm	4000-10,500/cmm
DIFFERENTIAL COUNT		
Neutrophils	**80 %**	40 - 70 %
Lymphocytes	**13 %**	20 -45 %
Monocytes	04 %	2 – 8 %
Eosinophils	03 %	1 – 5 %
Basophils	0.0 %	0 – 1 %
RBC	**4.78 mil/ cmm**	**4.5 -5.5 mil/ cmm**
Hb	**15.1 g /dl**	**13 – 18 g /dl**
PLATELETS	211,000/ cmm	150000–450000/cmm
ESR **PBF**	**07 mm in 1st hour** **Normochromic normocytic**	**<10 mm in 1st hour**

Urine R/M/E

TEST	RESULT
a)PHYSICAL EXAMINATION	
Colour	Straw
Appearance	Clear
b)CHEMICAL EXAMINATION	
Reaction	Acidic
Albumin	Trace
Sugar	Nil
c)MICROSCOPIC EXAMINATION	
Pus cell	0-2 / HPF
R.B.C.	Nil
Epithelial cells	1 – 2 / HPF
Casts	Nil

Liver Function Test

TEST	RESULT	REFERENCE
S.SGPT	19 IU/L	< 40 IU/L
Billirubin total	0.4 mg/dl	0.00-1.00 mg/dl
S. Albumin	4.50 g/dl	3.8 – 5.0
Prothrombin time	13.4 sec	11 – 13.5

During 23.11.2014 - 12.12.2014 In Tertiary Hospital

TEST	FINDINGS
HBsAg	Negative
Anti HBc Total	Negative
HCV-Ab	Negative
TPHA	Negative
Anti-HIV	Negative
Serum Creatinine	0.4 mg/dl (0.6 – 1.2mg/dL)
Anti Toxo – IgG	Negative
Mantoux Test (MT)	Negative
Serum Calcium	8.7 mg/dl (8.5 – 10.5mg/dL)
Chest X-Ray P/A view	Normal Finding

CSF Study	Findings	Reference Range
WBC Lymphocyte Count	10/mm^3	0 – 4/mm^3
RBC	0 /mm^3	0 mm^3
Protein	42.72mg/dL	15 – 45 mg/dL
Glucose	4.4mmol/L	2.8 – 4.4mmol/L
VDRL	Non-reactive	
Oligoclonal Band of IgG (Protein electrophoresis)	No OGB seen	

Further Investigations

Test	Findings	Referance Range
24 hours urinary Calcium	34 mg/day	100-300mg/day
ANA	Negative	
p ANCA	2.34 (Negative)	
c ANCA	2.50 (Negative)	
Serum ACE level	56 U/L	(8-65 U/L)
CMV Ab panels - IgM	Negative	
CMV Ab panels - IgG	Positive	
HSV Ab panels IgM	Negative	
HSV Ab panels IgG	Negative	

Echocardiography on 19.12.2014

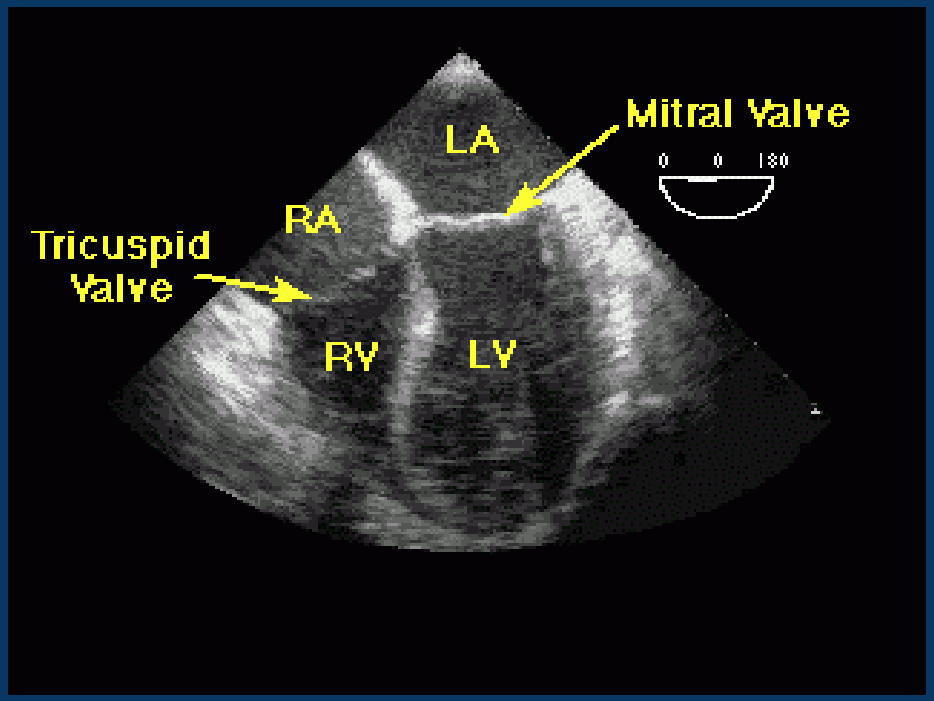

Echocardiographic findings are within the Normal Limit

MRI of BRAIN on 28.11.2014 in Tertiary Hospital

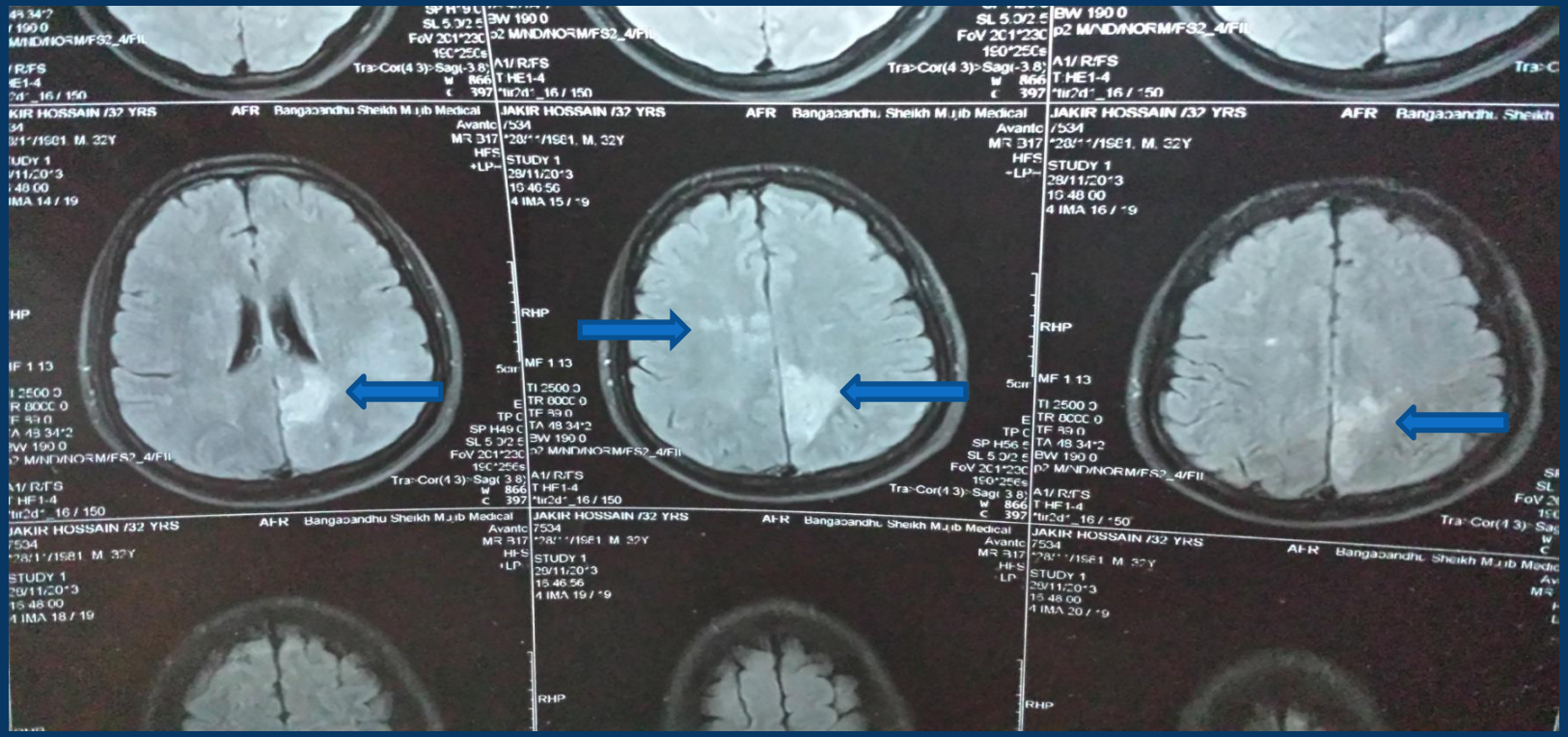

Features consistent with encephalitis associated with cortical laminar necrosis.

MRI of BRAIN on 19.12.2014 in DMCH

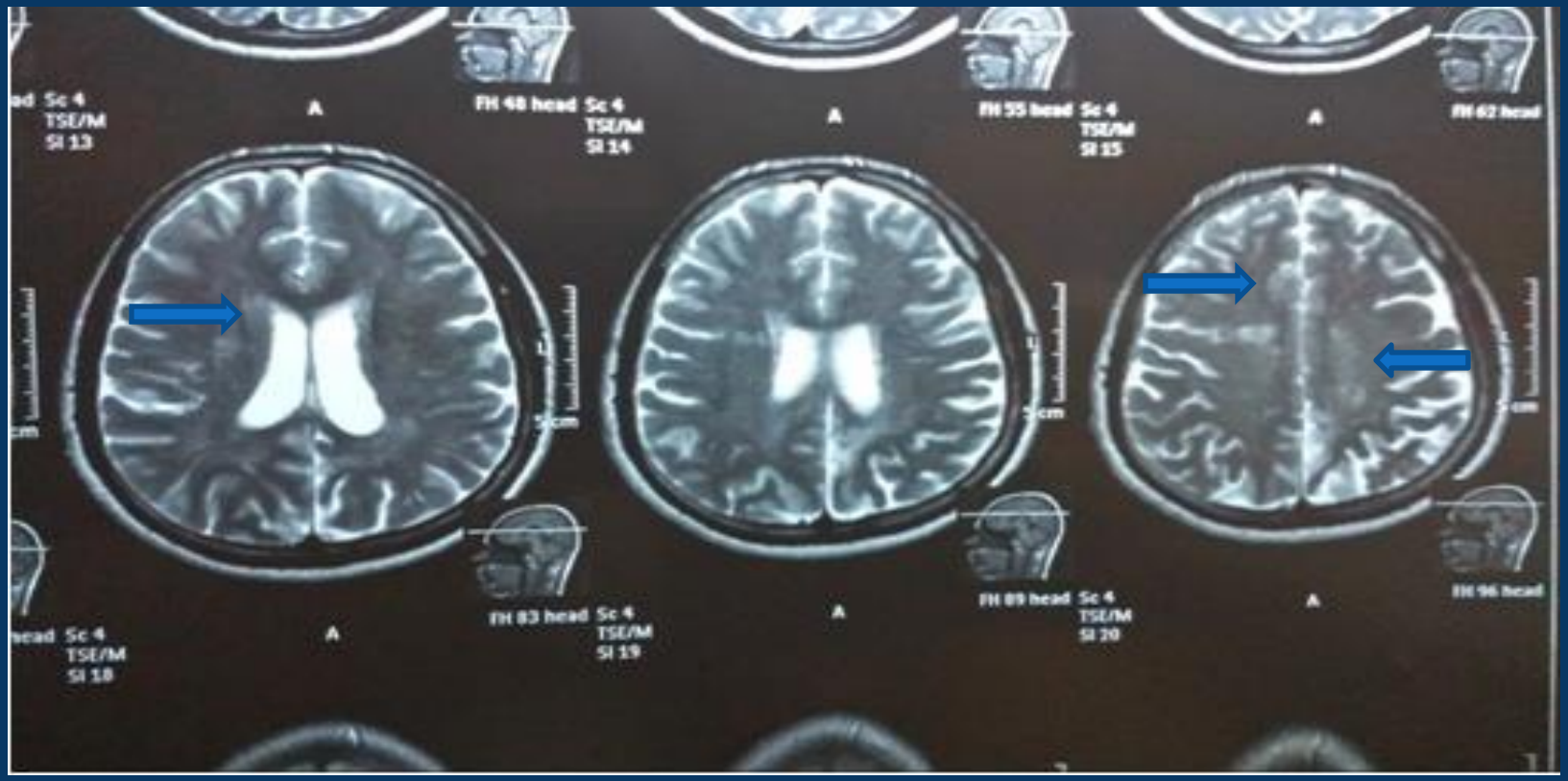

Features suggestive of Demyelinating Diseases

MRI of Spine on 19.12.2014

- Block vertebrae at c4/5 level.

- Central and both paracentral **disc bulge** at L4/5 level causing **thecal sac indentation**, mild spinal canal **stenosis** and bilateral neural foraminal **narrowing**.

- Central and both paracentral **disc bulge** at L5/S1 level causing **thecal sac indentation** and mild spinal canal **stenosis, no** neural foraminal **narrowing**.

MRA and MRV of Cerebral Vessels – 19.12.2014

Normal Study

Visual Evoked Potential (VEP) On 24.12.2014

- No waveform seen in right side
- Prolonged P100 latency in left side
- Advice: To correlate clinically

Confirmatory Diagnosis

MULTIPLE SCLEROSIS

Multiple Sclerosis

- Multiple Sclerosis a chronic disease characterised by inflammation , demyelination, gliosis (scarring), and neoronal loss.

- Course can be relapsing-remitting or progressive.

- Important cause of long standing disability in adults.

The McDonald criteria

Clinical presentation	Additional evidence required for diagnosis
≥ 2 attacks separated in **'time'** (at least 3 month apart) and **'space'** (involving different parts of CNS) **with** objective clinical evidence of **≥ 2** lesions	None
≥ 2 attacks separated in time and space, **but with** objective clinical evidence for only **one** reason	• Dissemination in **'space'** – MRI **or** • ≥ **2** MRI detected lesions consistent with MS and oligoclonal bands in CSF **or** • Await further clinical attack at different anatomical site
One attack with objective clinical evidence of **≥ 2** lesion in different parts of CNS	• Dissemination in **'time'** – Serial MRI scan **or** • Await further (2nd) clinical attack at different anatomical site
One attack with objective clinical evidence of only **one** lesion	• MRI demonstration of dissemination in **'space'** and **'time' or** • **≥ 2** MRI detected lesions with CSF showing oligoclonal bands and dissemination in **'time' or** • Await further (2nd) clinical attack at different anatomical site
Insidious neurological progression suggestive of MS	• CSF positive for oligoclonal bands **or** • Dissemination in **'space'** and **'time'** on MRI &/or abnormal **VER or** • Continued progression for a year

Thank you...