Clinical Importance of MRI in neurological disorder

Dr. Md. Tariqul Islam

MBBS. MD. FCPS.

Fellow (VIR), Singapore

Department of Radiology and Imaging

National Institute of Neurosciences and Hospital.

Agargaon, Dhaka.

- Radiology is the fastest advancing branch of medical science.
- MRI takes the lead in this rapid march of advancement.
- MR has emerged as strong modality, which gives final answer in many conditions of our body system.

- **MR Neuroimaging** includes the use of various techniques to image the structure & function of the brain with the help of MRI.

- Neuroimaging falls into two broad categories:

- **Structural imaging &**

- **Functional imaging**

- **MRI** uses **magnetic fields** and **radio waves** to produce high quality two- or three-dimensional images of brain structures without use of **ionizing radiation (X-rays)** or radioactive tracers.

Principles of Interpretation of Neuroimaging

- To be able to interpret MR images ,apart from anatomical and pathological knowledge , knowing basics of pulse sequences and their specific uses is essential.

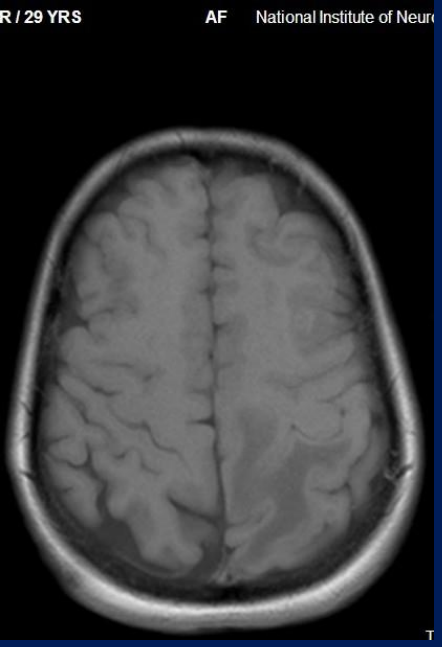
R / 29 YRS
AF
National Institute of Neur

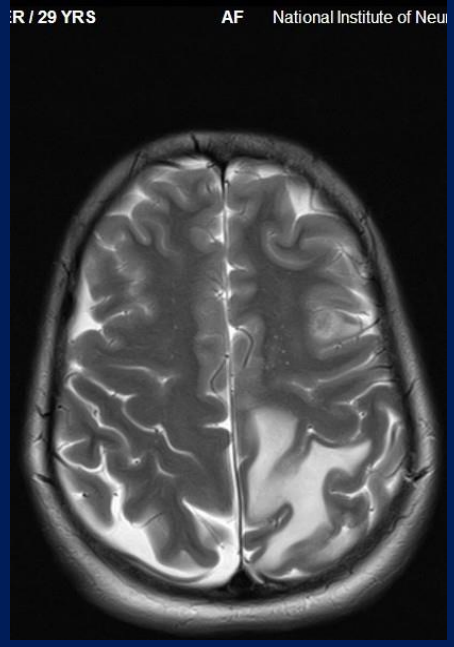
R / 29 YRS
AF
National Institute of Neu

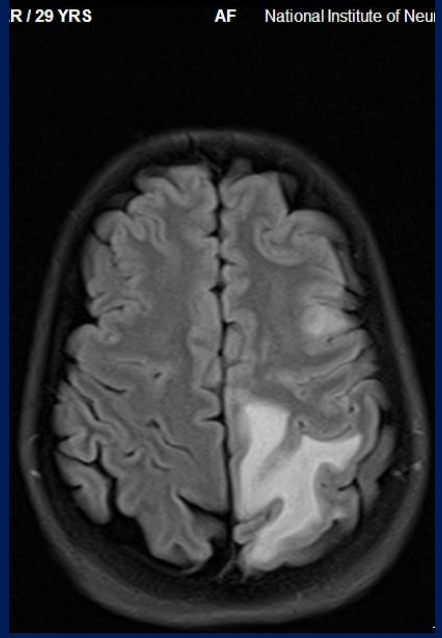
R / 29 YRS
AF
National Institute of Neu

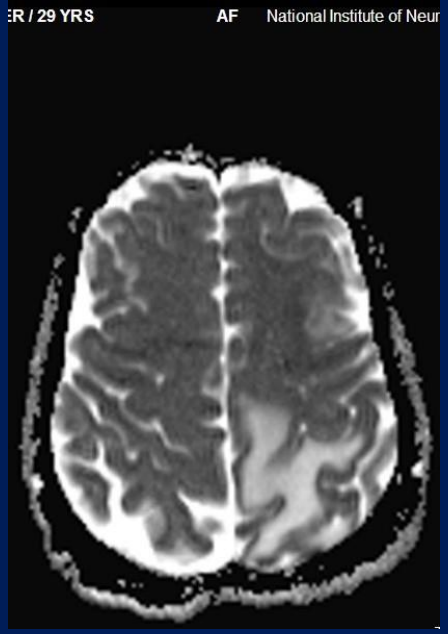
R / 29 YRS
AF
National Institute of Neur

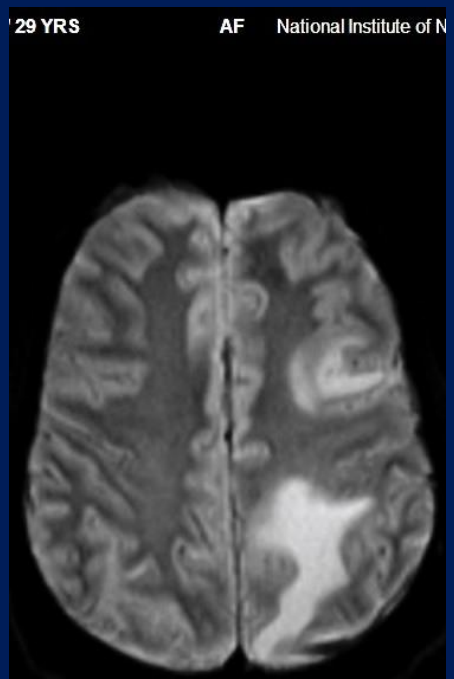
29 YRS
AF
National Institute of N

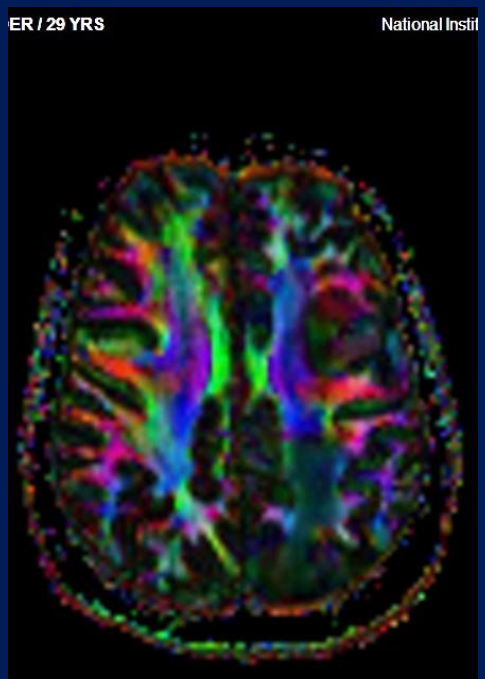
ER / 29 YRS
National Instit

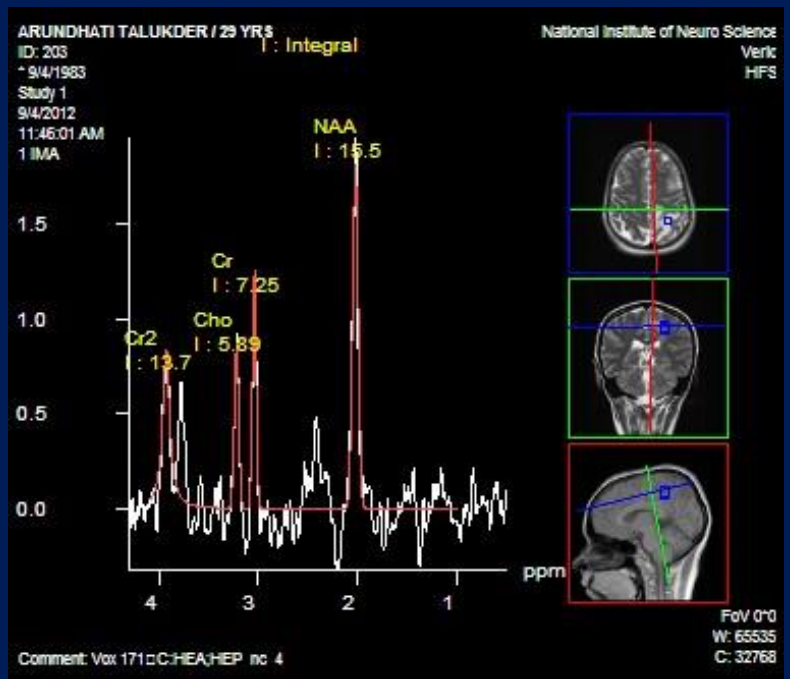
ARUNDHATI TALUKDER / 29 YRS
ID: 203
^ 9/4/1983
Study 1
9/4/2012
11:46:01 AM
1 IMA
I : Integral
National Institute of Neuro Science
Verio
HFS
NAA
I : 15.5
Cr
I : 7.25
Cho
I : 5.89
Cr2
I : 13.7
1.5
1.0
0.5
0.0
4
3
2
1
ppm
FoV 0*0
W: 65535
C: 32768
Comment: Vox 171□C:HEA;HEP nc 4

MR images of some tissues

- **Fat :** **Bright** on T1WI, **less bright** on T2WI.
- **Air:** Dark on all sequences.
- **Cortical bone: Dark** on T1 and T2WI.
- **Medullary bone** depends on degree of fat replacement.

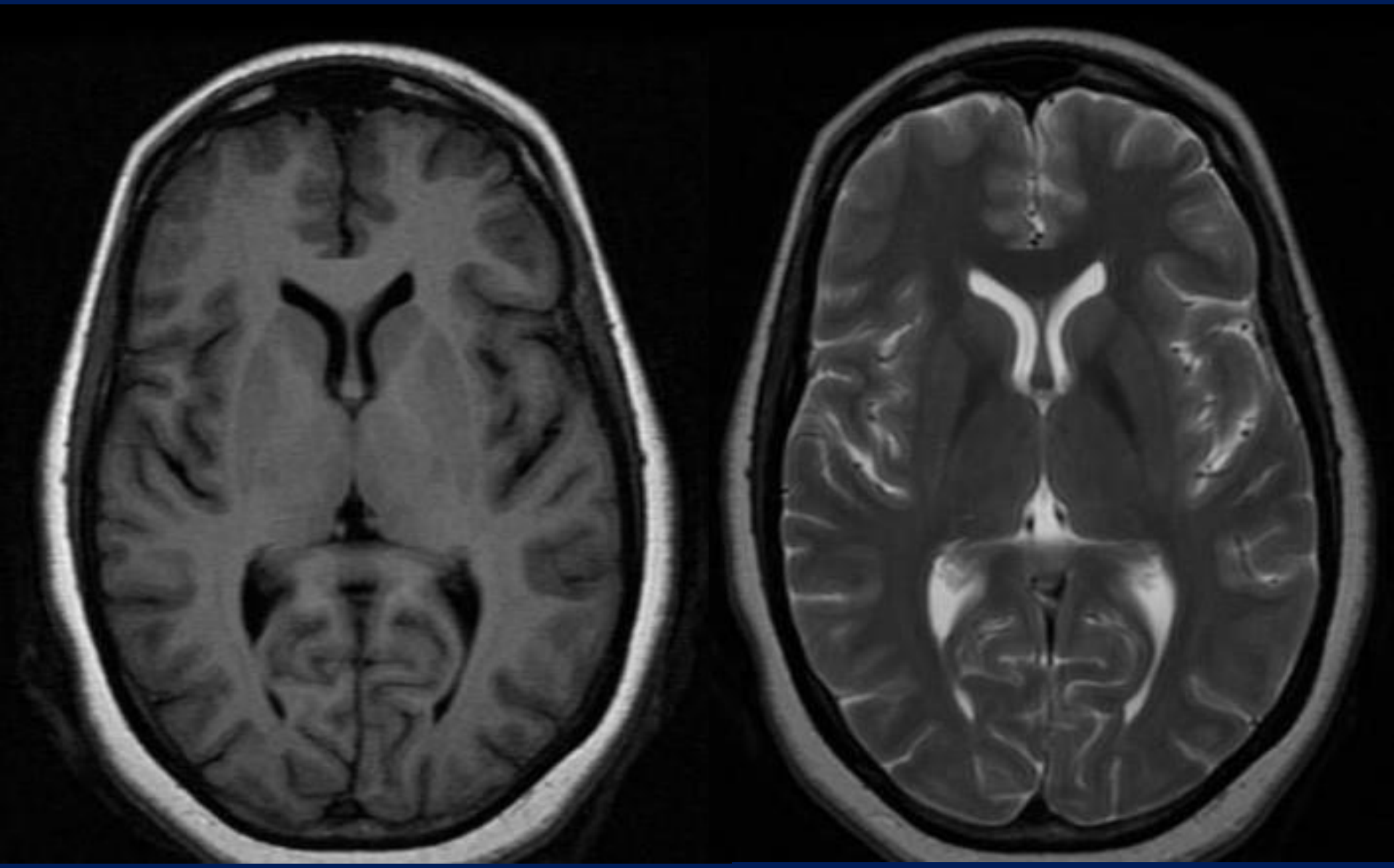

- **Calcifications** are usually **DARK** on both T1 and T2WI, exceptions are there.
- Lesions having high content of protenacious material, methemoglobin and **cholesterol debris** appear **bright** onT1WI.

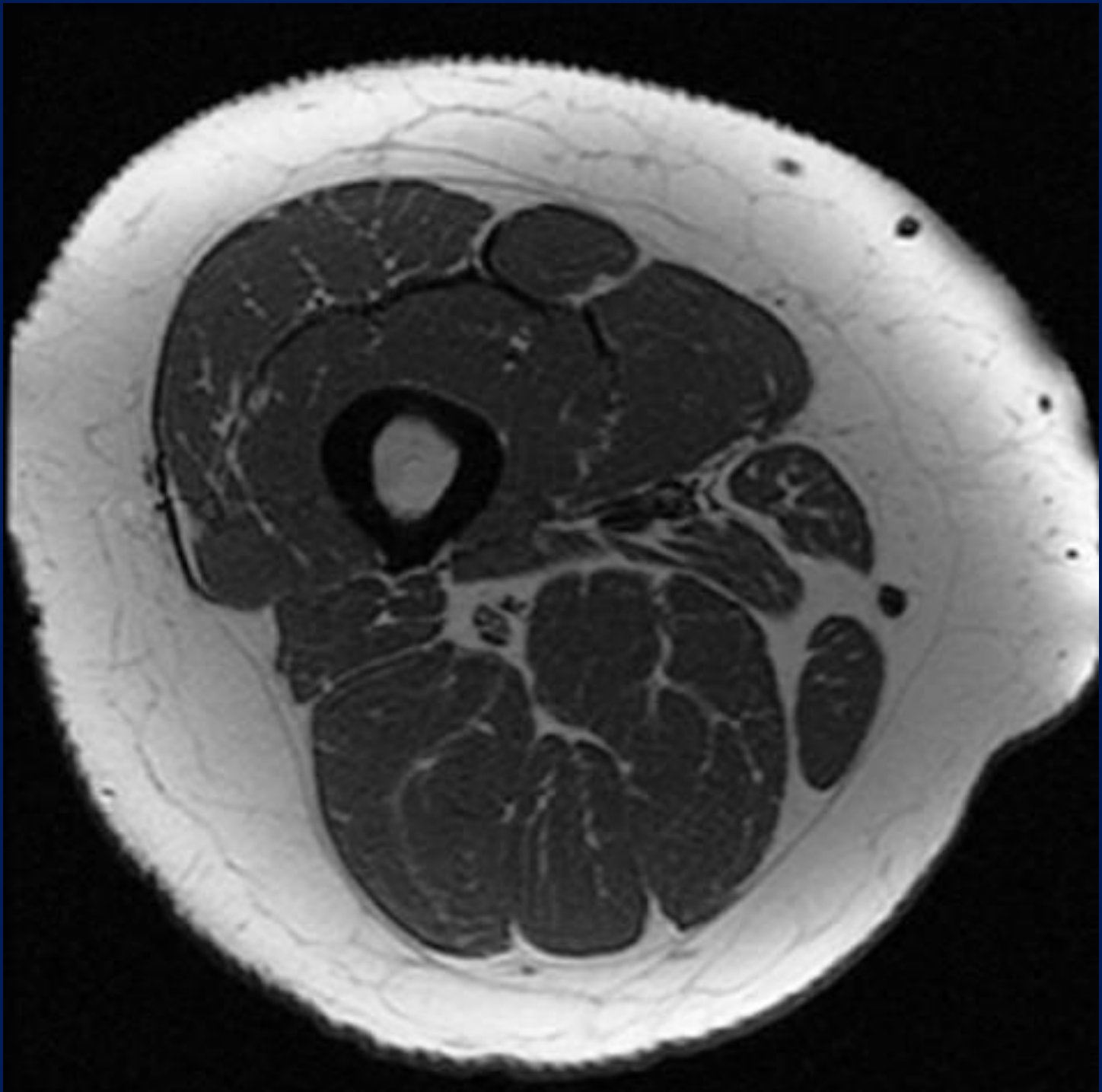

Basal ganglia

Signal changes in MRI

- **Bright basal ganglia** on T1WI seen in Hepatolenticular degeneration,
  - Mangenese deposition in parenteral nutrition,
  - Some calcifications
  - Hemorrhage
  - Neurofibromatosis.

- **Bright basal ganglia** on T2WI seen in Lymphoma
  - Ischemia
  - Neurodegenerative disease (Wilsons disease, Parkinson's Disease)
  - Toxin (CO poisoning)

- **Dark basal ganglia** on T2WI seen in ---------

  Childhood hypoxia

  – Old age

  – Multiple sclerosis

  – Parkinson’s Disease, Hemosiderin deposition

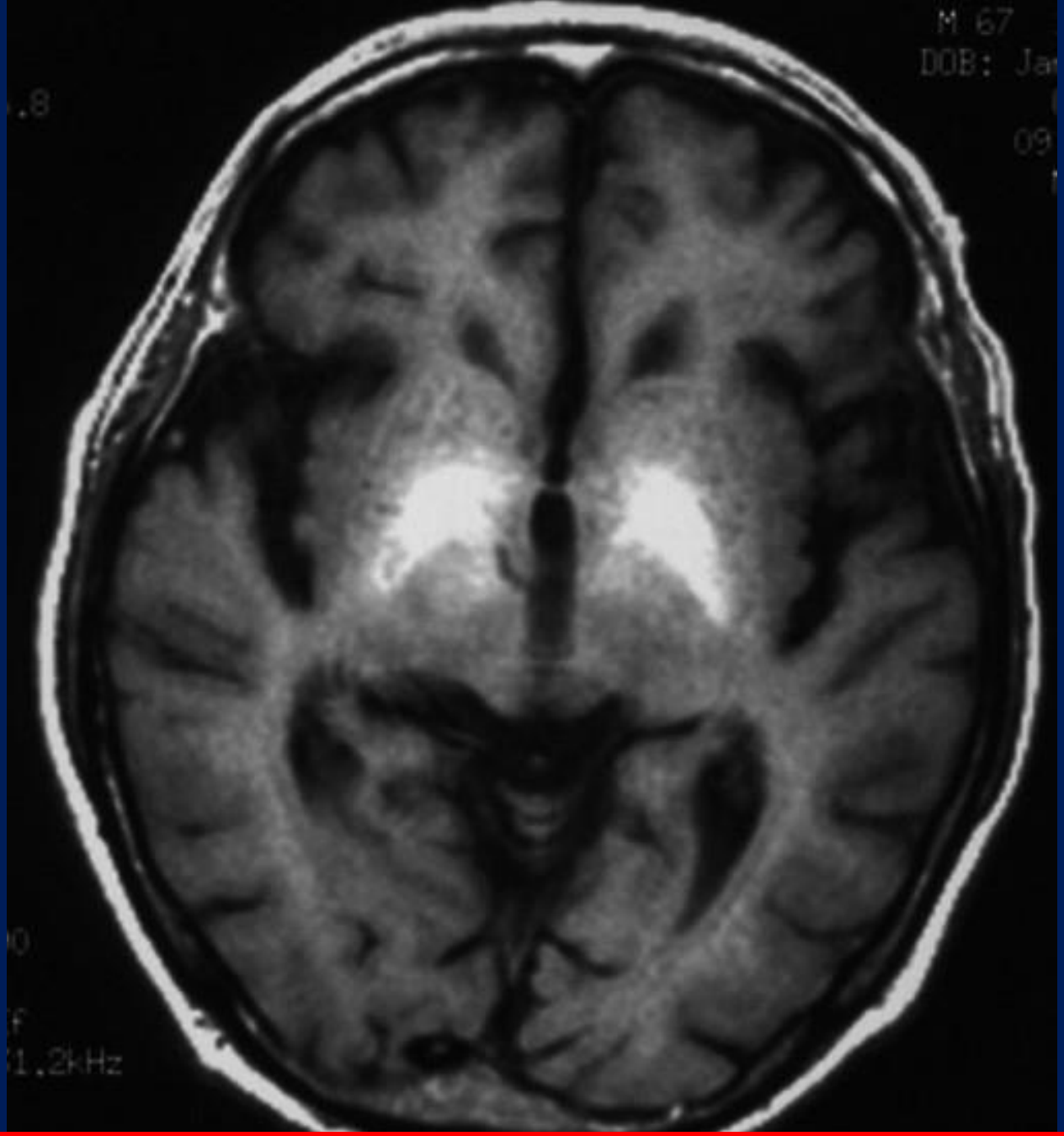

T1WI - hyperintensity of basal nuclei in chronic hepatic encephalopathy

- **Conventionally T1W images for anatomy and T2WI for pathology.**

MR spectroscopy

- Allow tissue to be interrogated for the presence and concentration of various metabolites.
- Various Peaks
  - lactate peak: lipid peak: alanine peak: N-acetylaspartate (NAA) peak: GABA peak: glutamine / glutamate peak: citrate peak: creatine peak: choline peak: myo-inositol peak:

Observable proton metabolites

Metabolite	Properties
Lipid	Products of brain destruction
Lactate	Product of anaerobic glycolysis
NAA	Neuronal markers
Glutamine/ GABA	Neurotransmitters
Creatine	Energy metabolism
Choline	Cell membrane turnover marker
Myo - inisitol	Glial cell marker
Alanine	Present in meningiomas.

Glioma

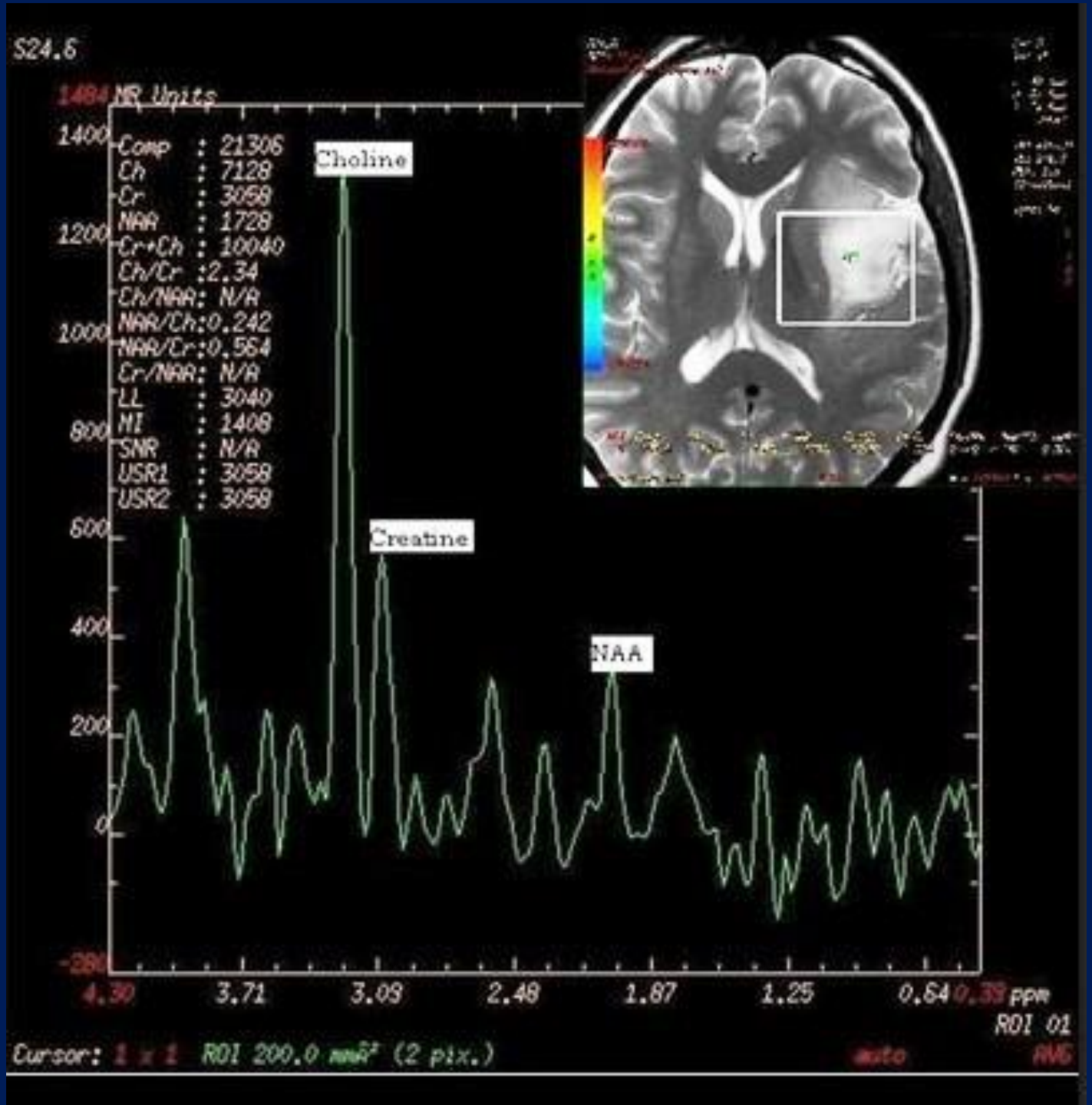
S24.6
NR Units
Comp : 21306
Ch : 7128
Cr : 3058
NAA : 1728
Cr+Ch : 10040
Ch/Cr :2.34
Ch/NAA: N/A
NAA/Ch:0.242
NAA/Cr:0.564
Cr/NAA: N/A
LL : 3040
MI : 1408
SNR : N/A
USR1 : 3058
USR2 : 3058
Choline
Creatine
NAA
1400
1200
1000
800
600
400
200
0
4.30
3.71
3.08
2.48
1.87
1.25
0.64
ppm
ROI 01
Cursor: 1 x 1 ROI 200.0 mm² (2 pix.)
auto
AVG

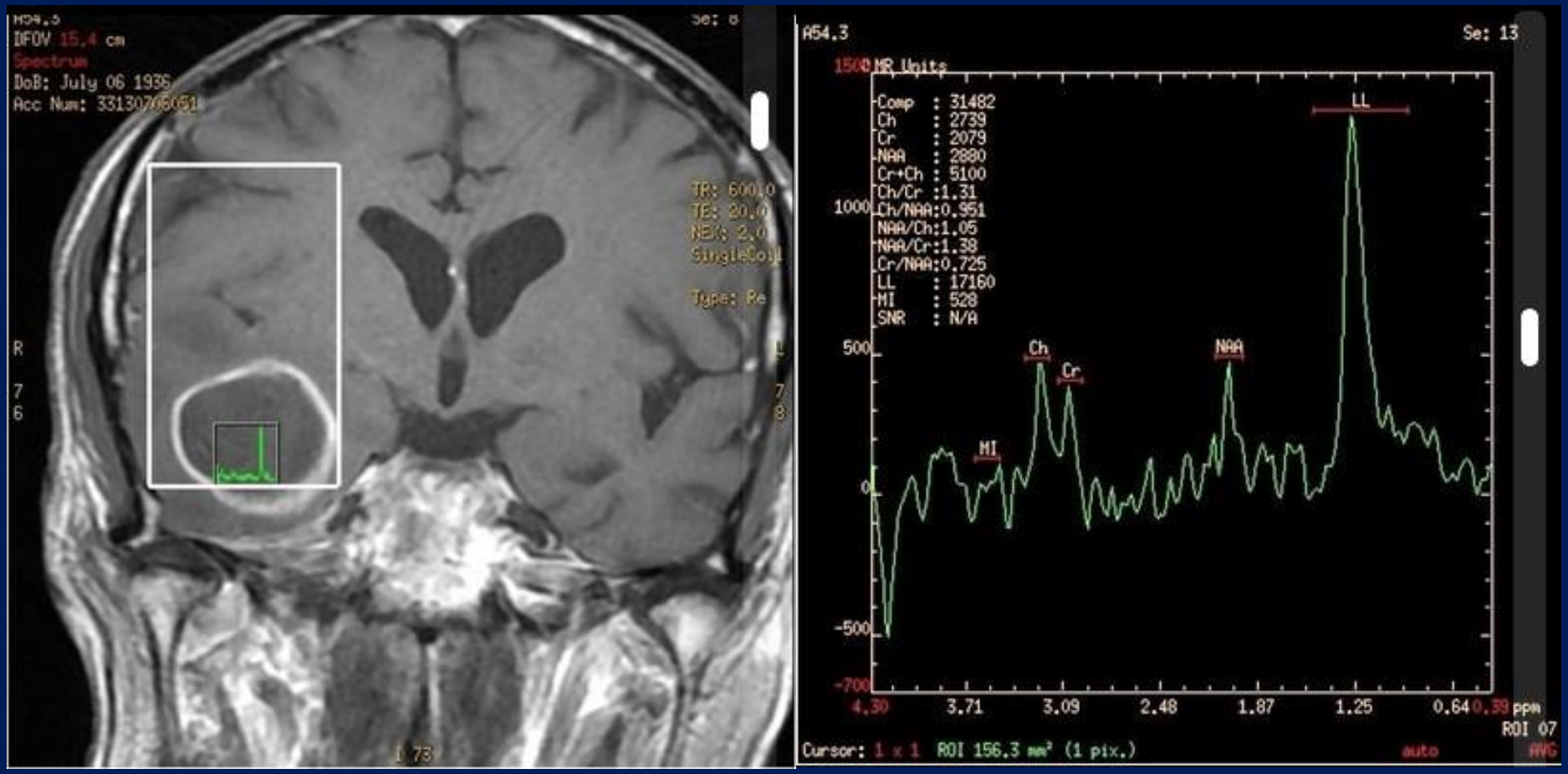

Cerebral abscess

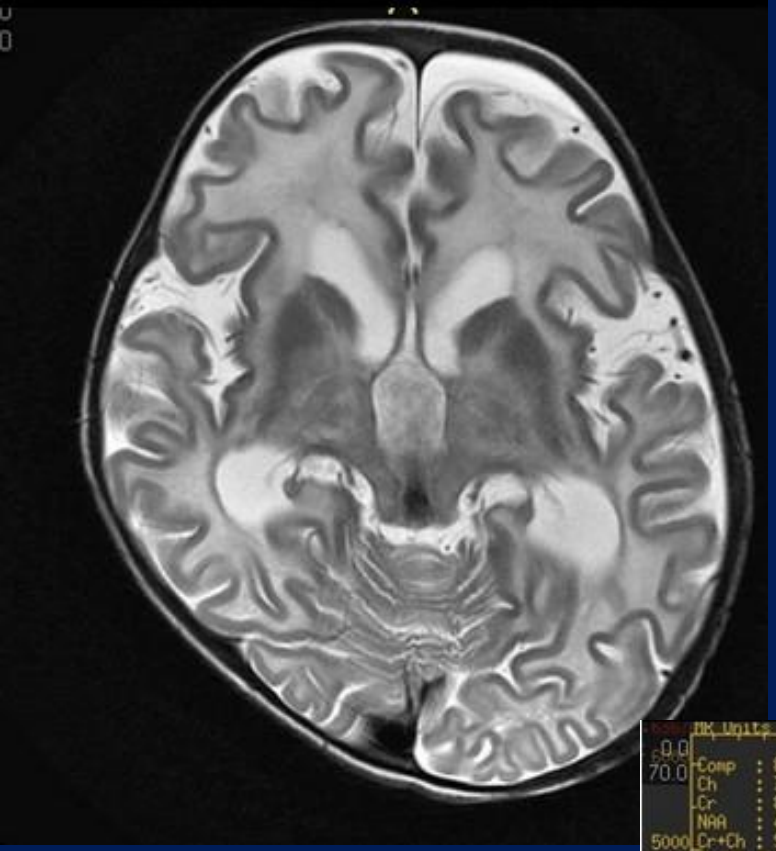

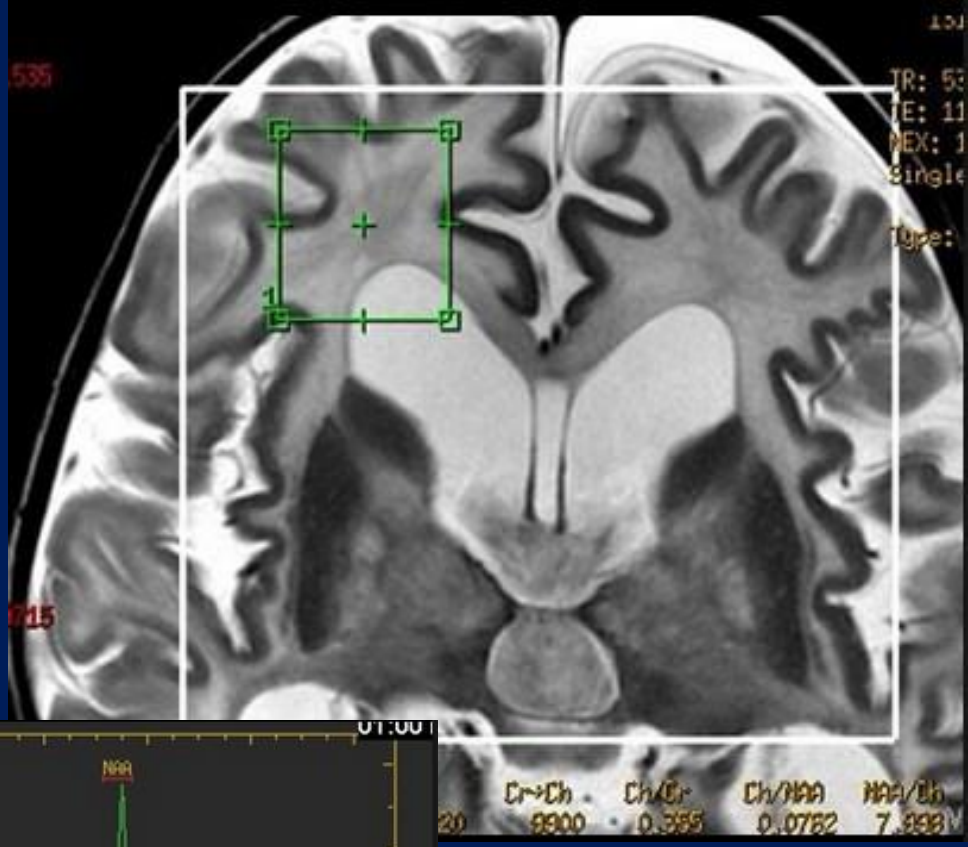

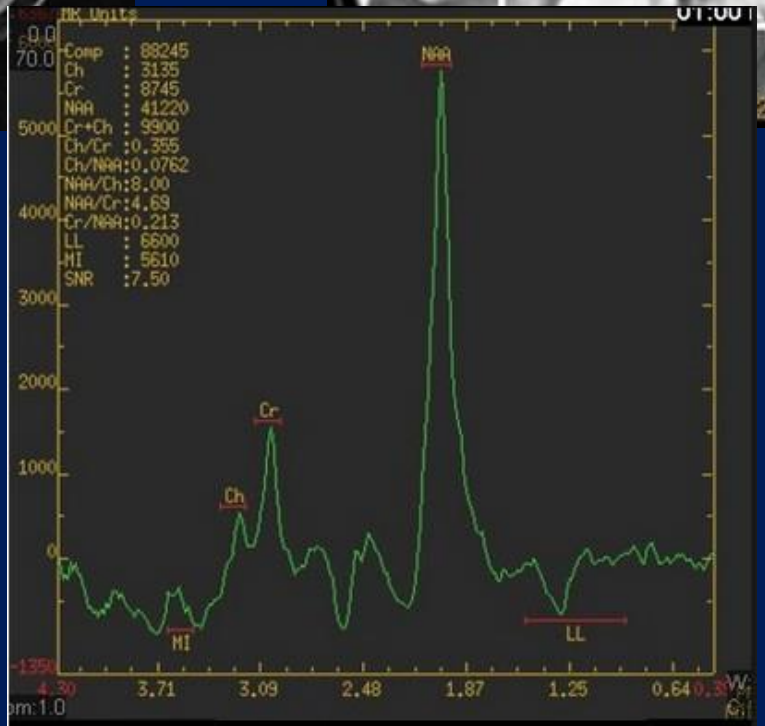

Canavan disease

MRS helpful in

- Glioma
- Non-glial tumours
- Radiation effects
- Ischaemia and infarction
- Infection
- Hepatic encephalopathy
- White matter diseases
- Mitochondrial disorders

Stroke imaging

- DWI for acute infarct.
- **Gradient hemo for acute bleed.**
- Fast flair for subarachnoid hge.
- TOF MR angiography for vessel status.
- Infarcts at periphery with hemorrhage, go for MRV… venous sinus thrombosis.

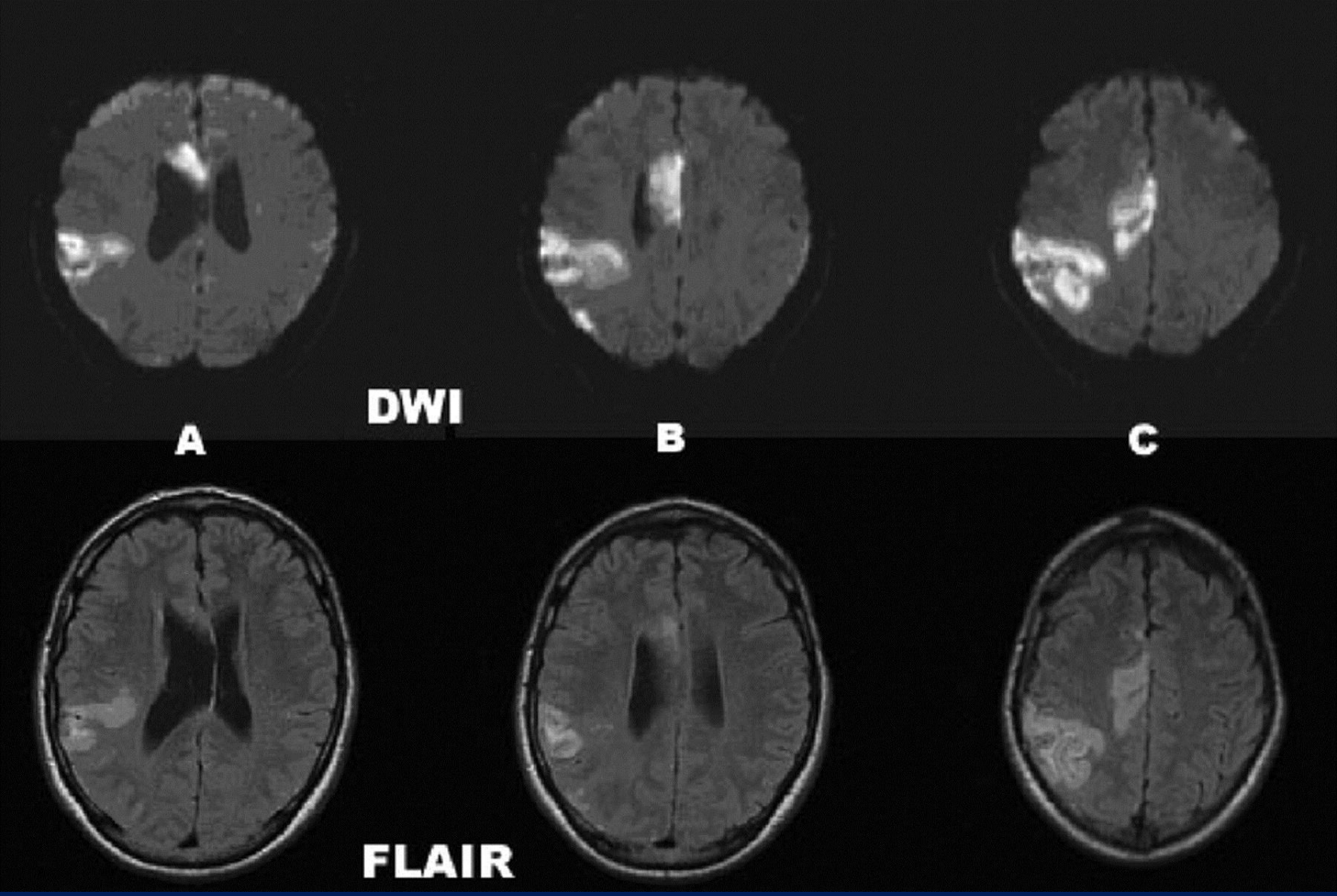

- *DWI and FLAIR showing the acute stroke in the right parietal lobe and anterior corpus callosum*

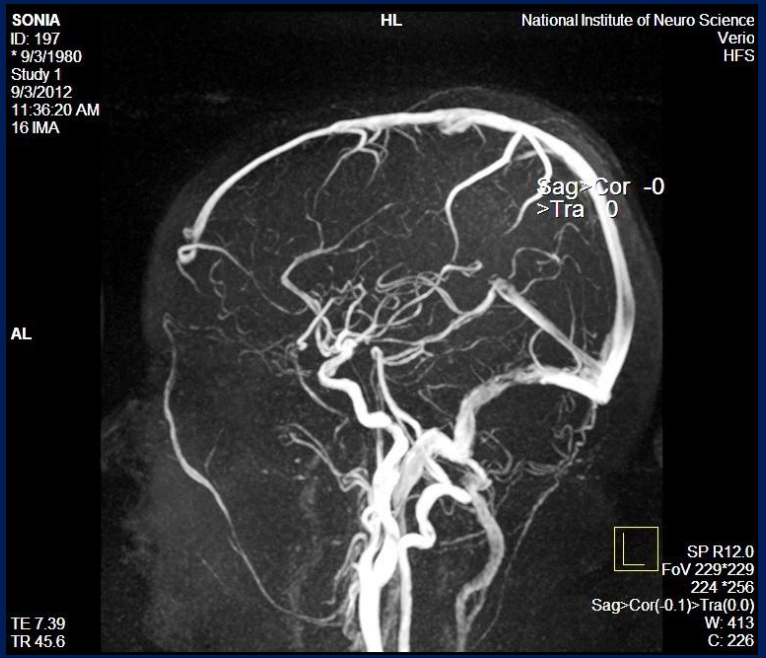
SONIA
ID: 197
* 9/3/1980
Study 1
9/3/2012
11:36:20 AM
16 IMA
HL
National Institute of Neuro Science
Verio
HFS
Sag>Cor -0
>Tra 0
AL
SP R12.0
FoV 229*229
224 *256
Sag>Cor(-0.1)>Tra(0.0)
W: 413
C: 226
TE 7.39
TR 45.6

RUHUL AMIN
ID: 182
* 9/1/1962
Study 1
9/1/2012
12:51:51 PM
1 IMA
HPR
National Institute of Neuro Science
Verio
HFS
Sag>Tra -3
>Cor -0
PF
SP R5.2
FoV 199*199
331 *384
Sag>Tra(-3.2)>Cor(-0.3)
W: 458
C: 361
TE 3.6
TR 21

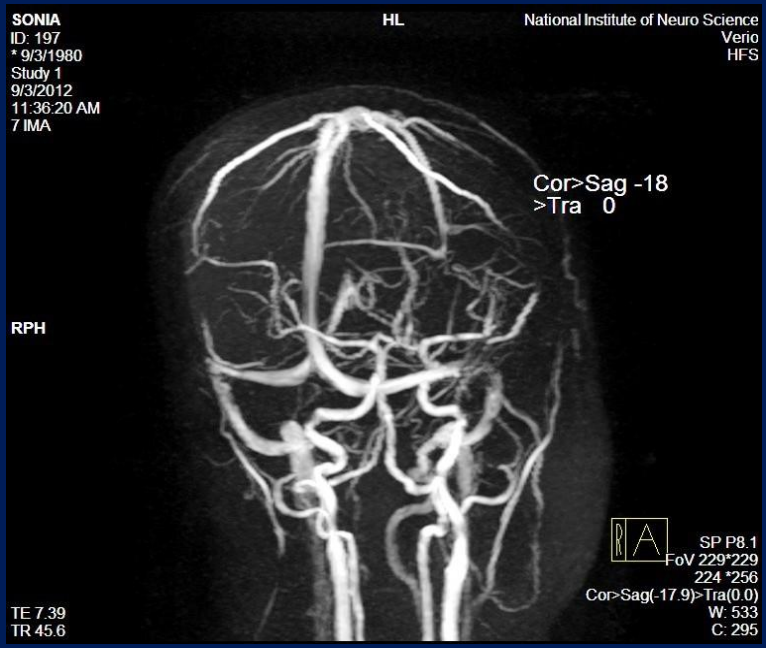
SONIA
ID: 197
* 9/3/1980
Study 1
9/3/2012
11:36:20 AM
7 IMA
HL
National Institute of Neuro Science
Verio
HFS
Cor>Sag -18
>Tra 0
RPH
SP P8.1
FoV 229*229
224 *256
Cor>Sag(-17.9)>Tra(0.0)
W: 533
C: 295
TE 7.39
TR 45.6

RUHUL AMIN
ID: 182
* 9/1/1962
Study 1
9/1/2012
1:03:54 PM
10 IMA
HAL
National Institute of Neuro Science
Verio
HFS
Cor>Tra -6
RHA
SP P7.7
FoV 219*219
187 *384
Cor>Tra(-5.8)
W: 352
C: 256
TE 3.6
TR 21

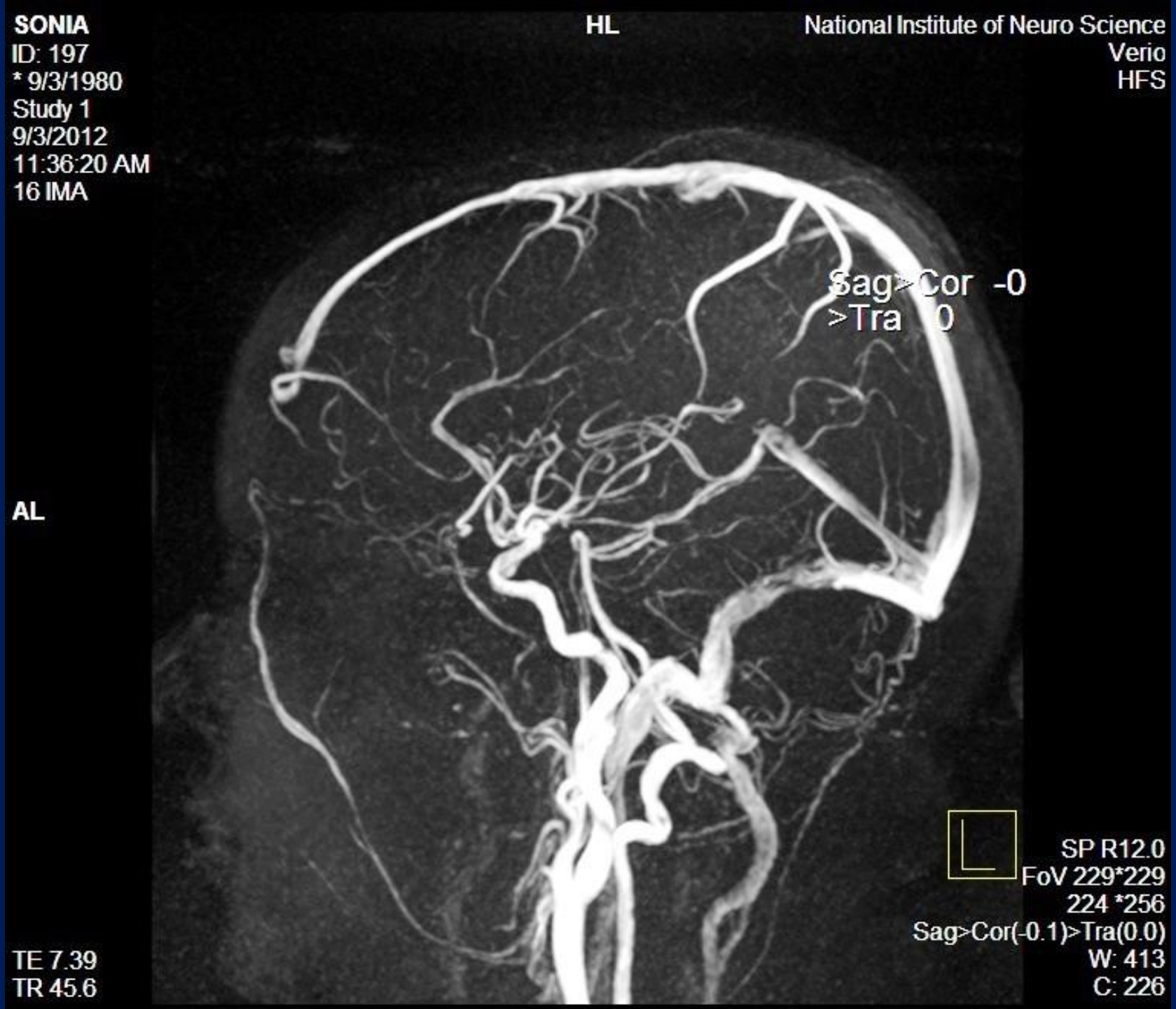
SONIA
ID: 197
* 9/3/1980
Study 1
9/3/2012
11:36:20 AM
16 IMA
HL
National Institute of Neuro Science
Verio
HFS
Sag>Cor -0
>Tra 0
AL
SP R12.0
FoV 229*229
224 *256
Sag>Cor(-0.1)>Tra(0.0)
W: 413
C: 226
TE 7.39
TR 45.6

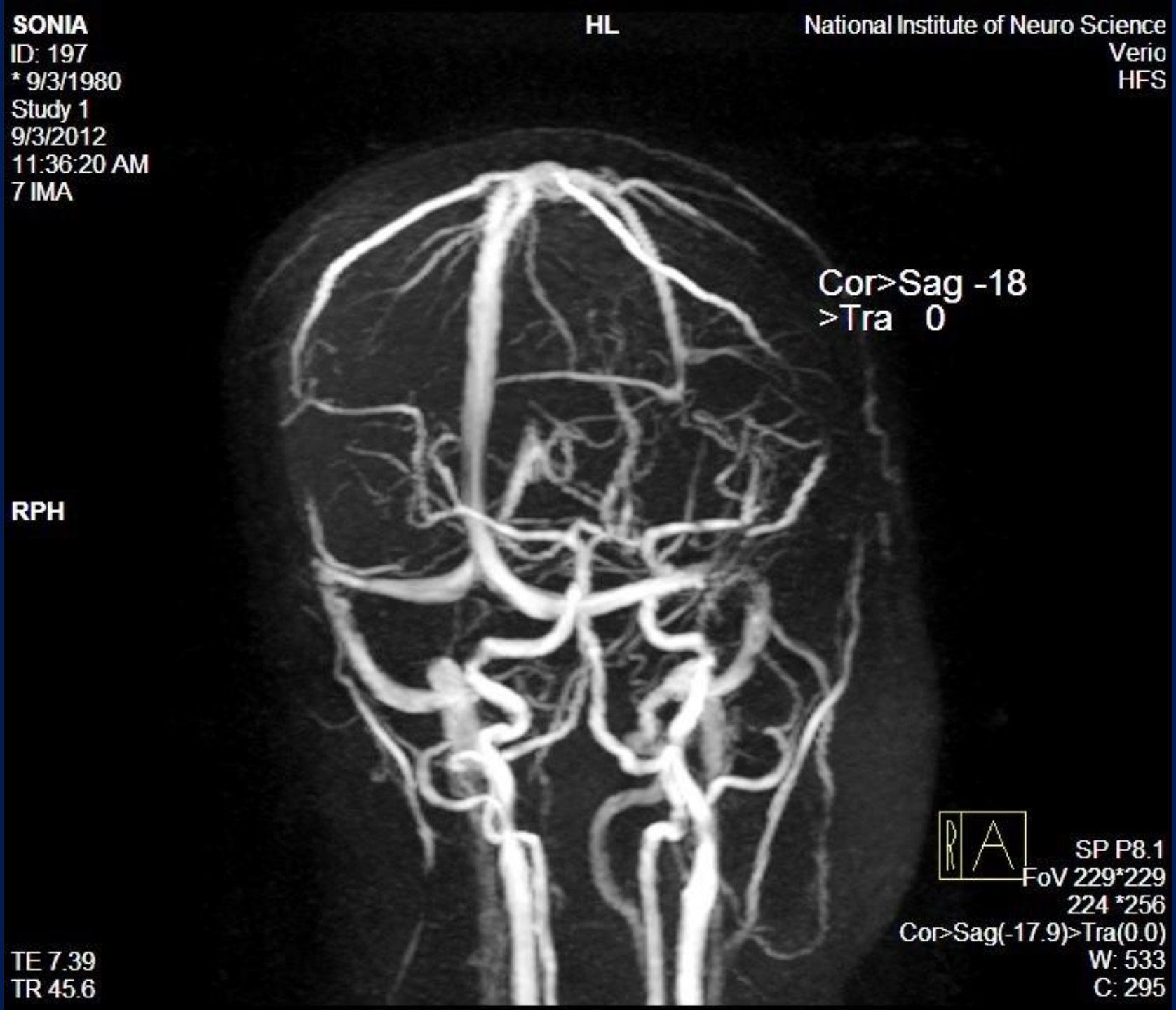
SONIA
ID: 197
* 9/3/1980
Study 1
9/3/2012
11:36:20 AM
7 IMA
HL
National Institute of Neuro Science
Verio
HFS
Cor>Sag -18
>Tra 0
RPH
SP P8.1
FoV 229*229
224 *256
Cor>Sag(-17.9)>Tra(0.0)
W: 533
C: 295
TE 7.39
TR 45.6

RUHUL AMIN
ID: 182
* 9/1/1962
Study 1
9/1/2012
1:03:54 PM
10 IMA
HAL
National Institute of Neuro Science
Verio
HFS
Cor>Tra -6
RHA
A
SP P7.7
FoV 219*219
187 *384
Cor>Tra(-5.8)
W: 352
C: 256
TE 3.6
TR 21

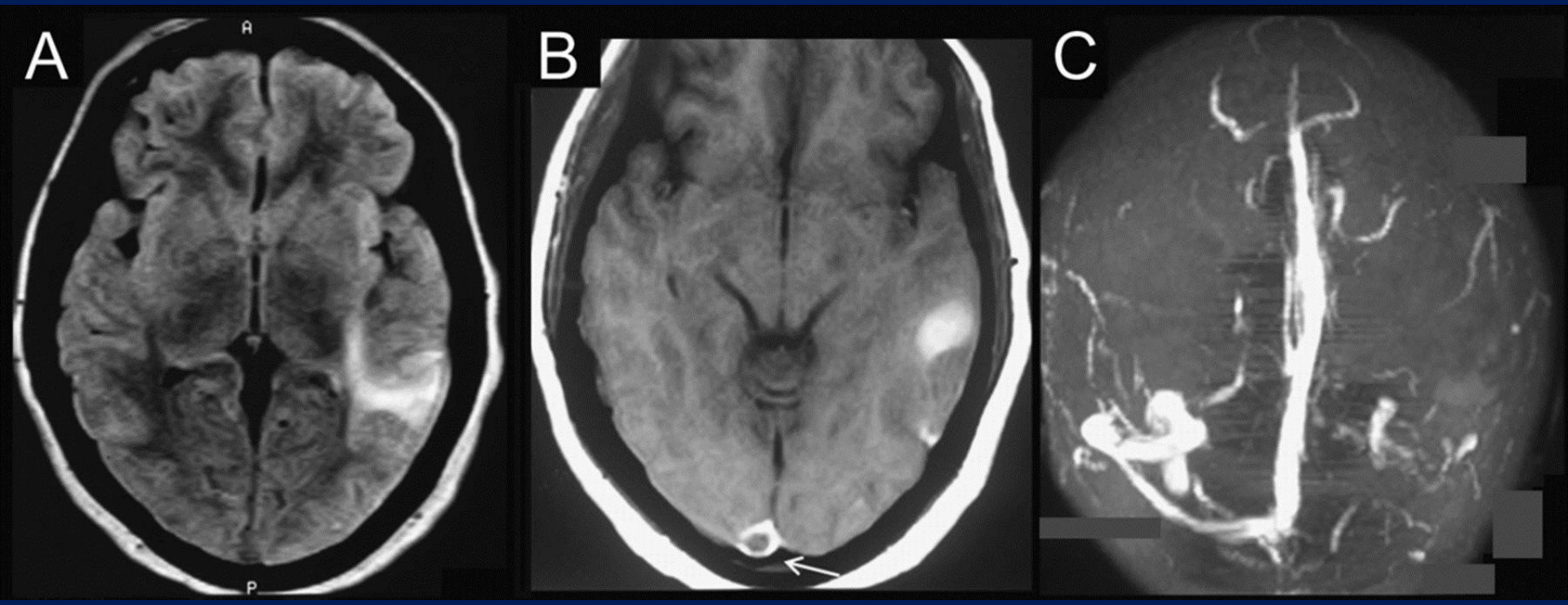

- **(A) noncontrast T1WI shows acute left temporal hemorrhagic infarct and (B) filling defect in the superior sagittal sinus (arrow) on gadolinium-enhanced T1 sequence. (C) Magnetic resonance venography shows left-sided sigmoid and transverse sinus thrombosis.**

T1- mixed intensity signals from the straight sinus and vein of Galen (thrombosis) with corpus callosum splenium swelling.

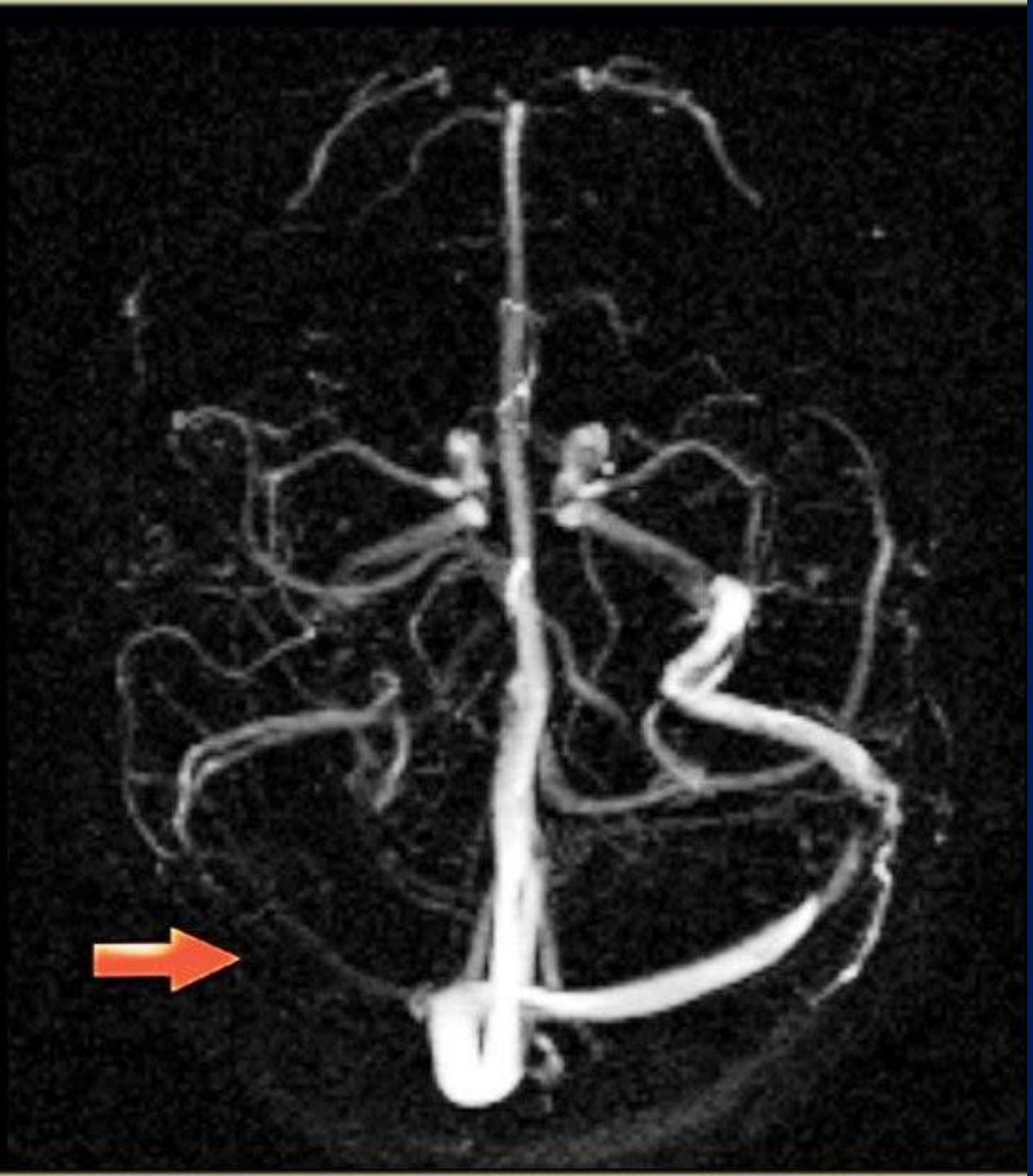

- **The right transverse sinus and jugular vein have no signal due to thrombosis in MRV**

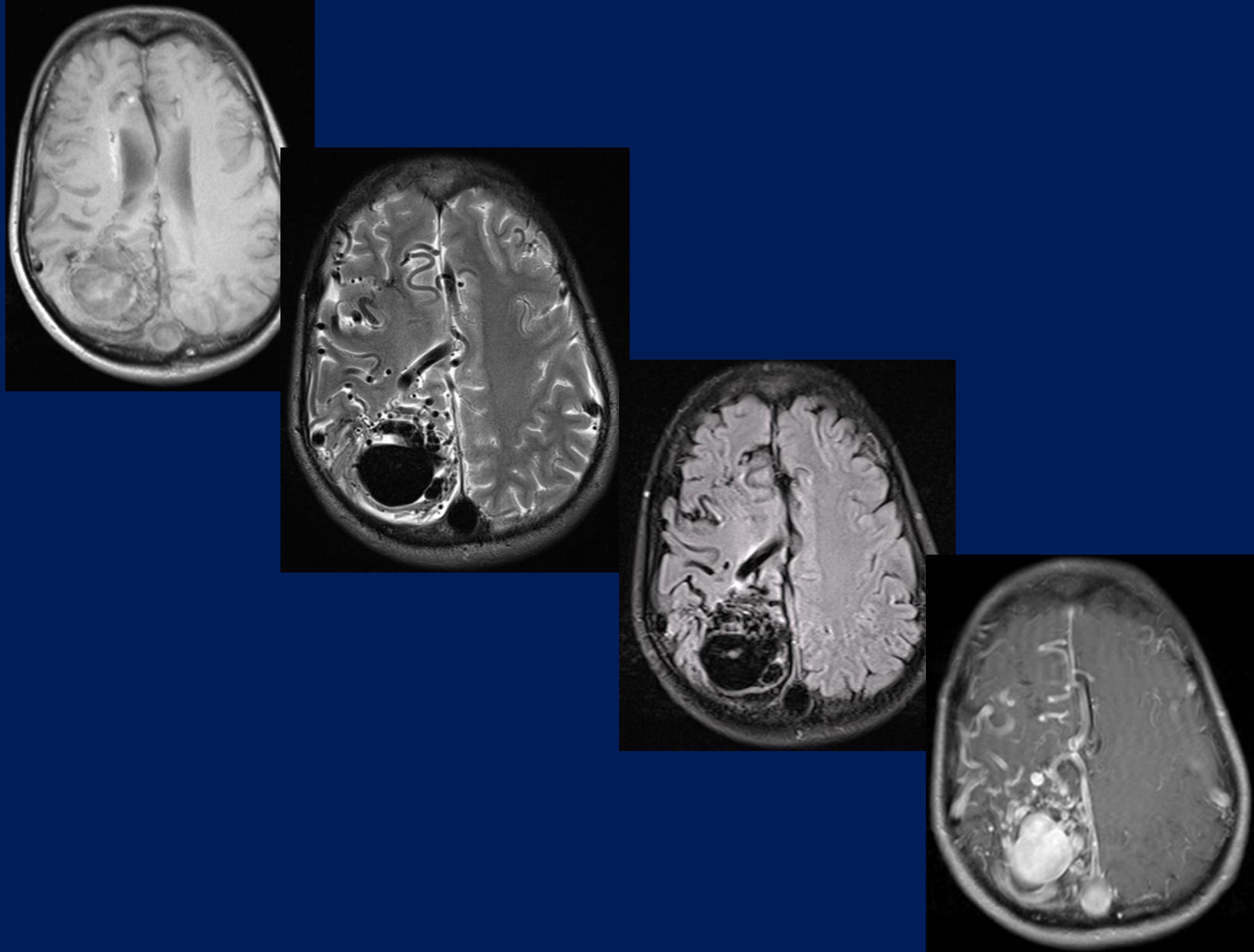

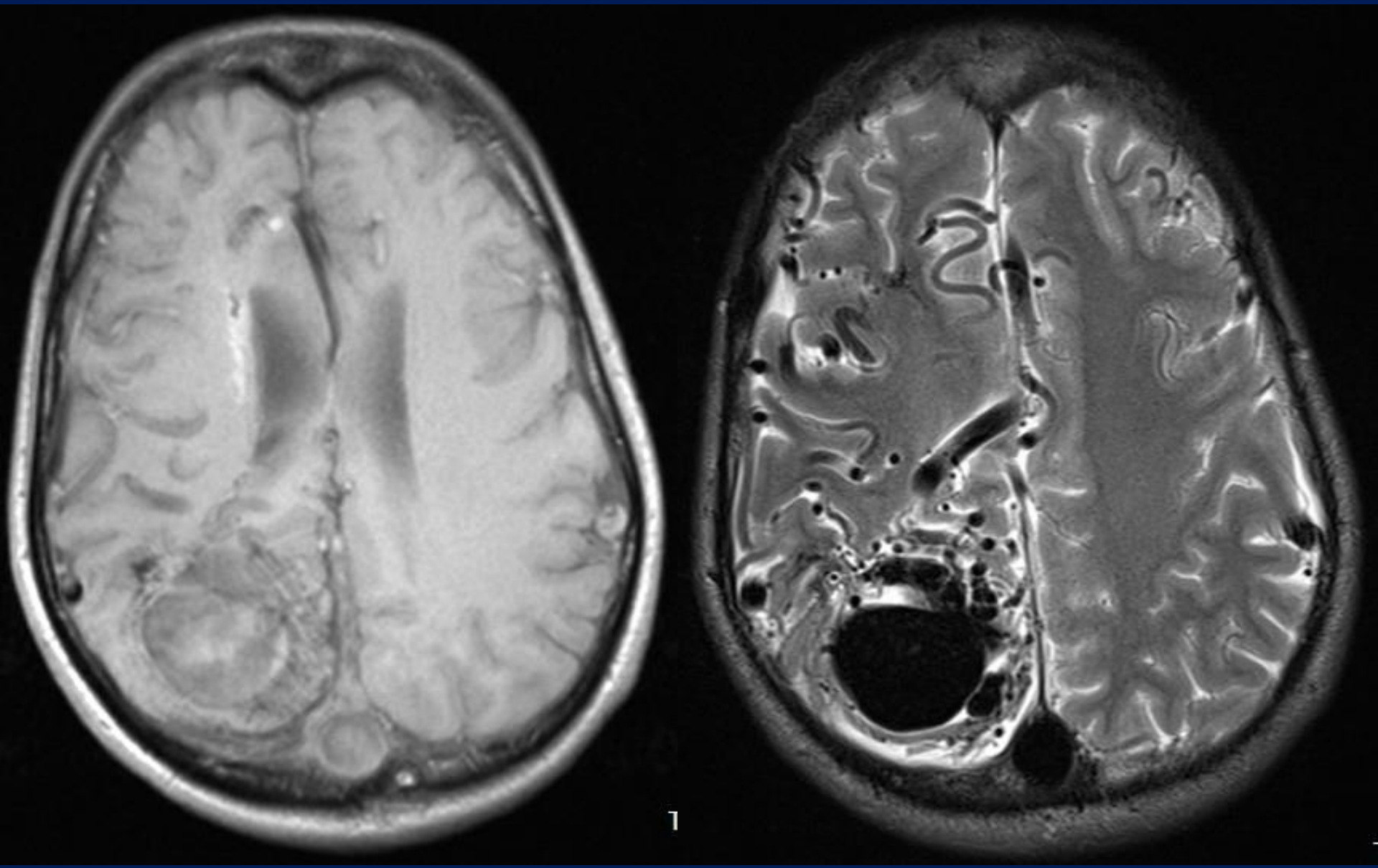
1

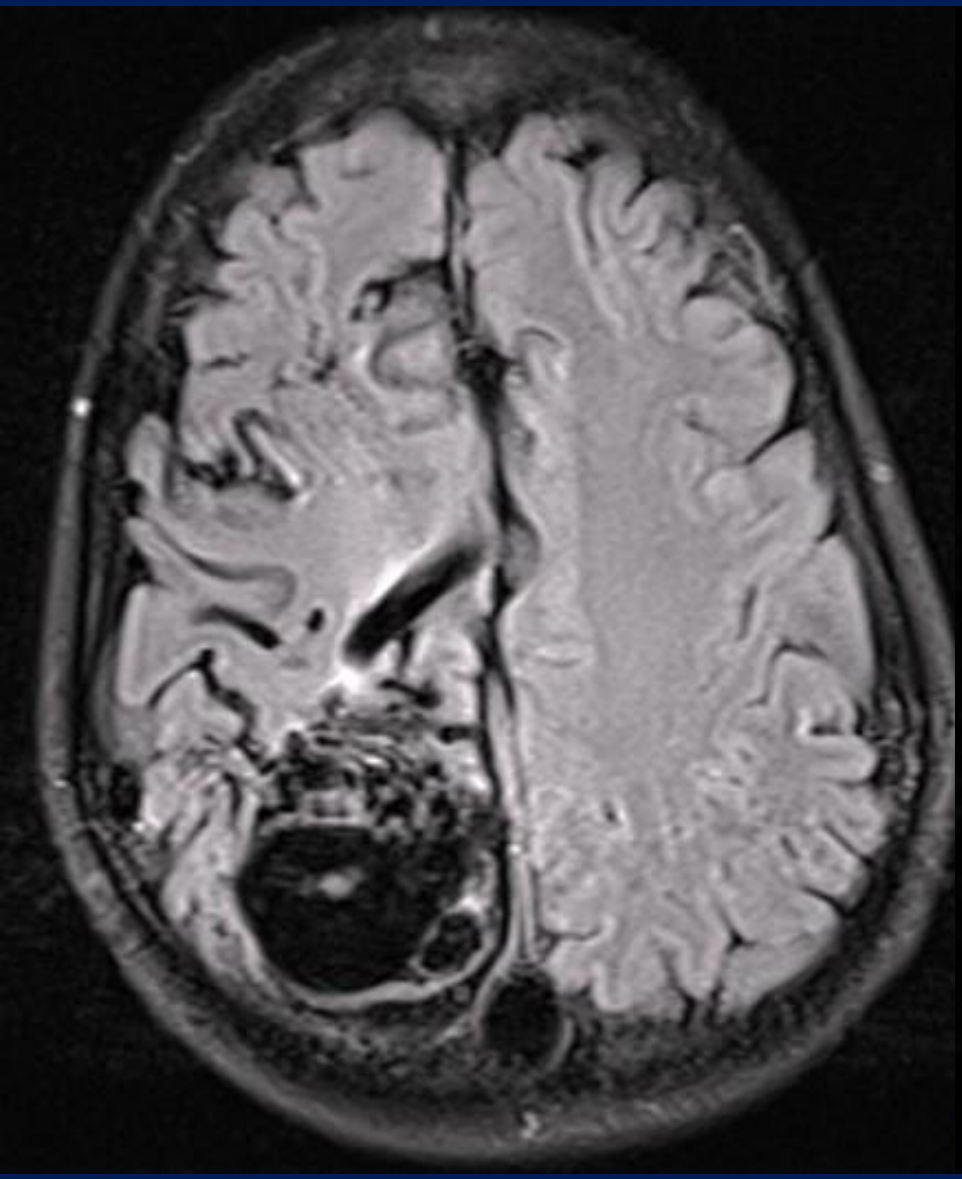

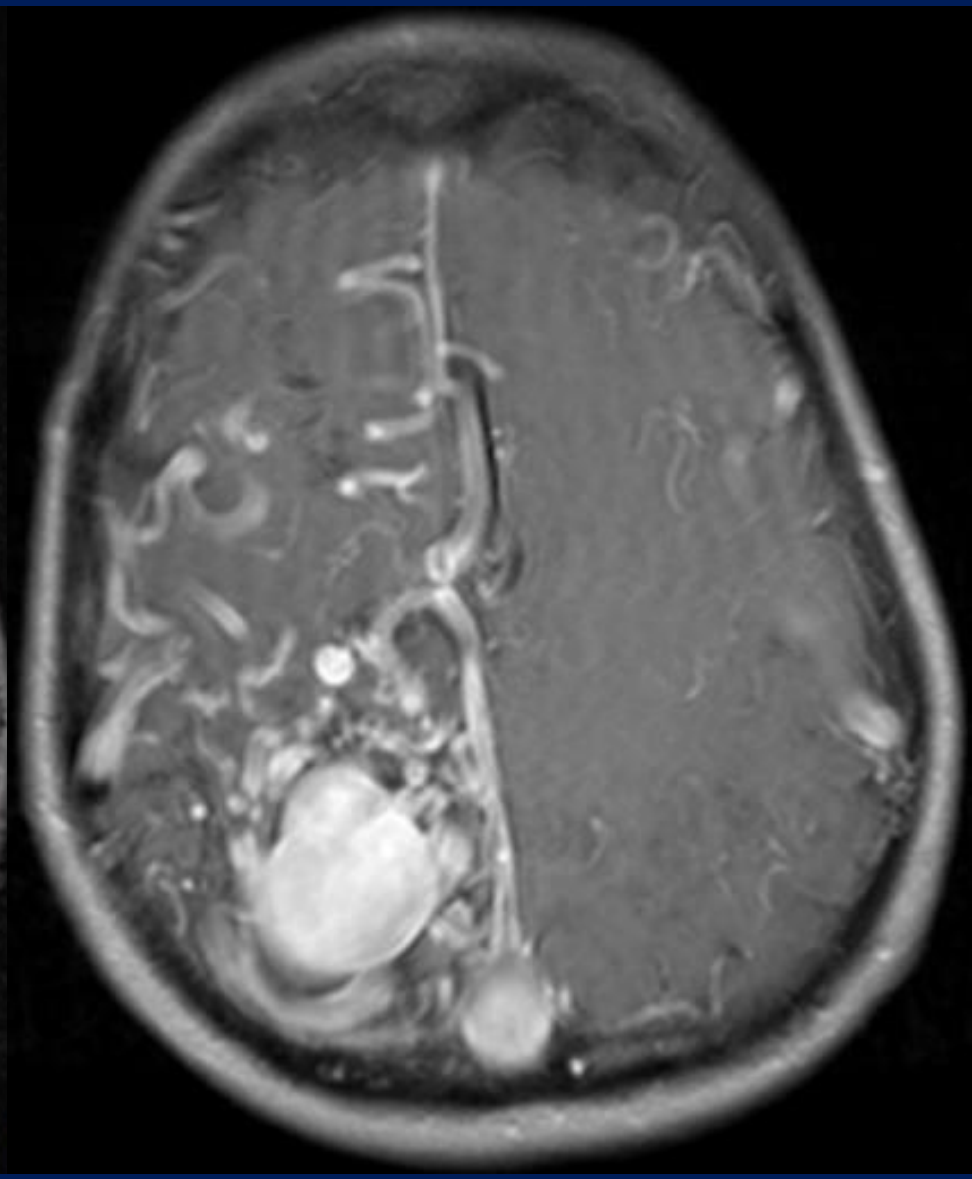

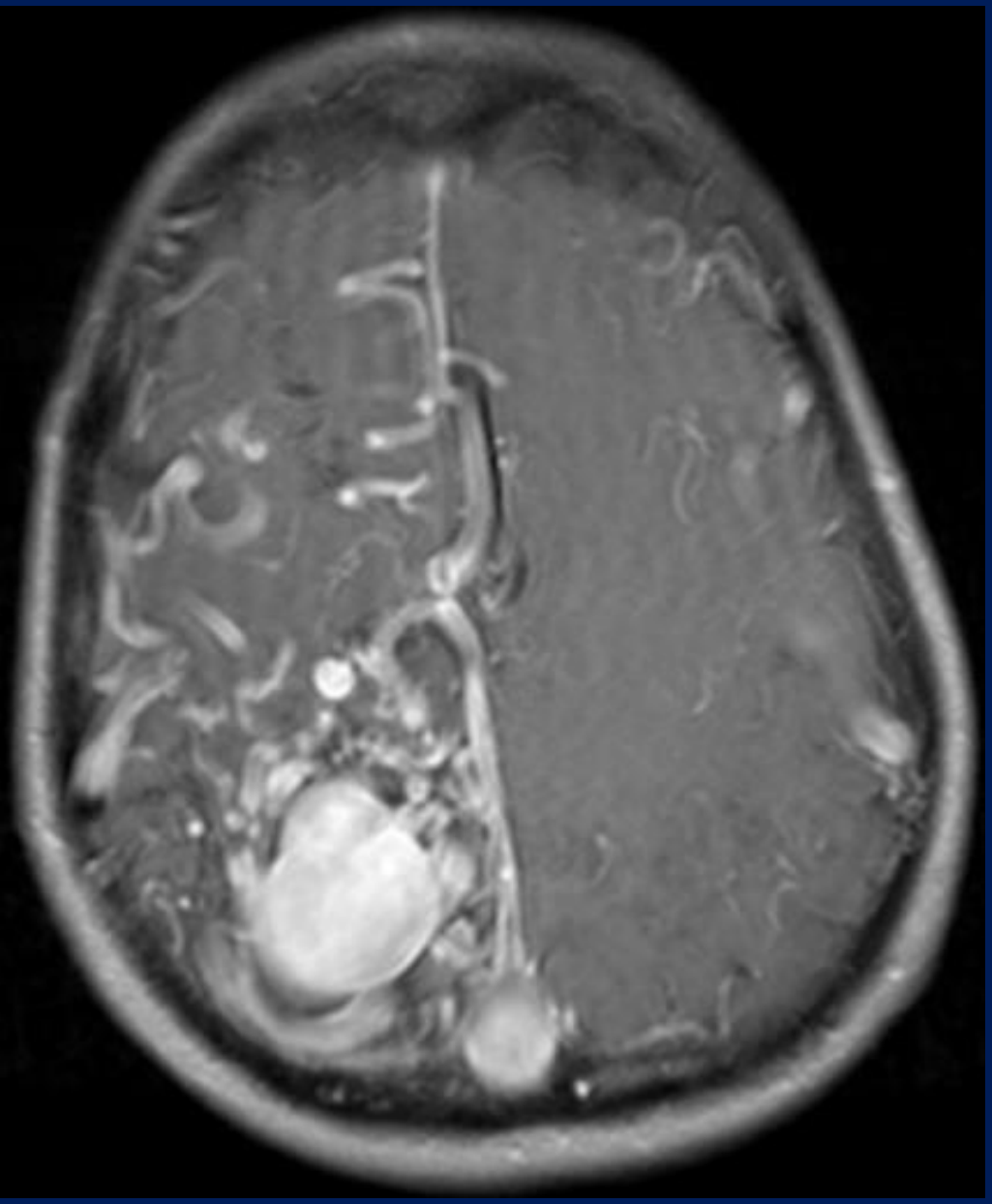

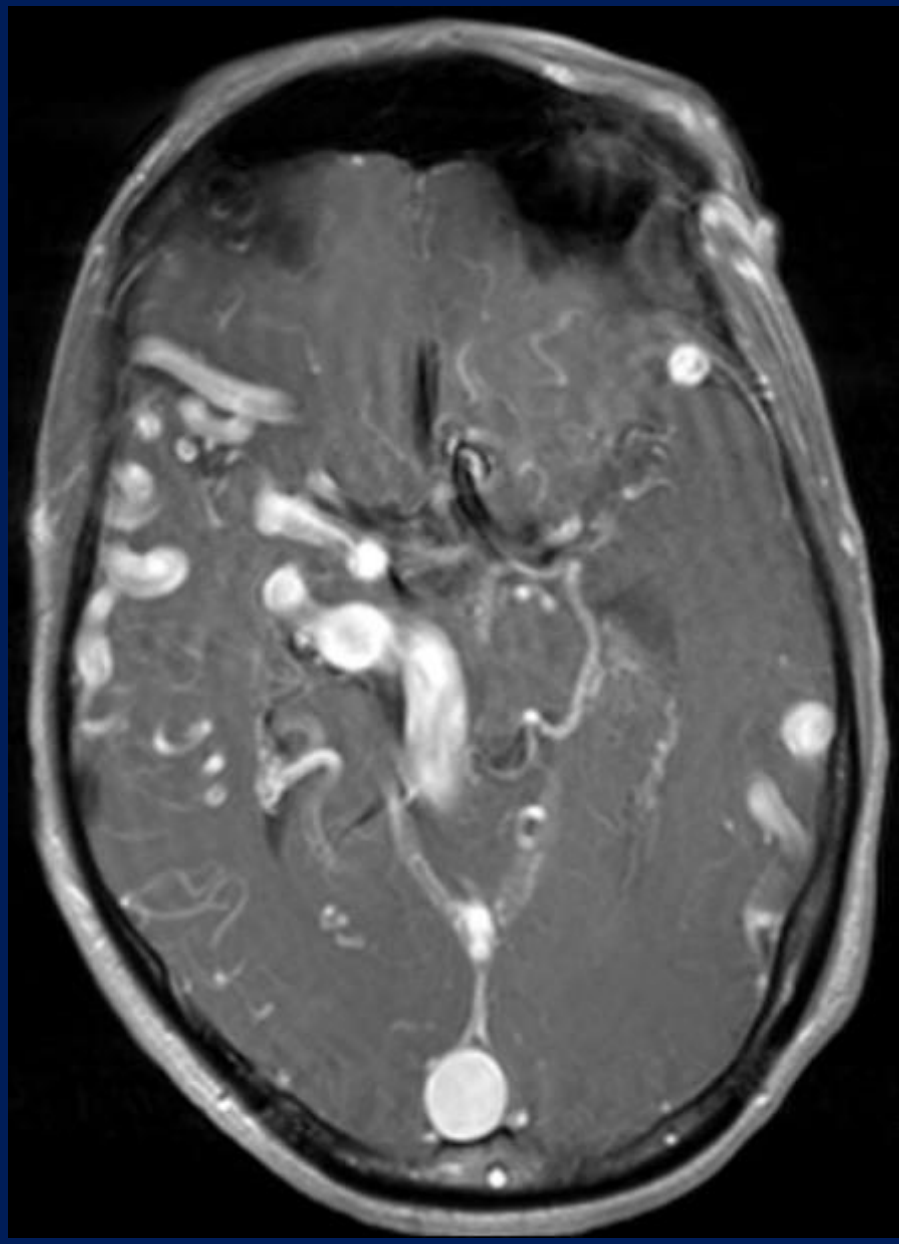

Tumour imaging

- MRI best modality
- Intravenous contrast should be given.
- Tumor enhancement suggest break in blood brain barrier.
- For tumor vascularity perfusion imaging.

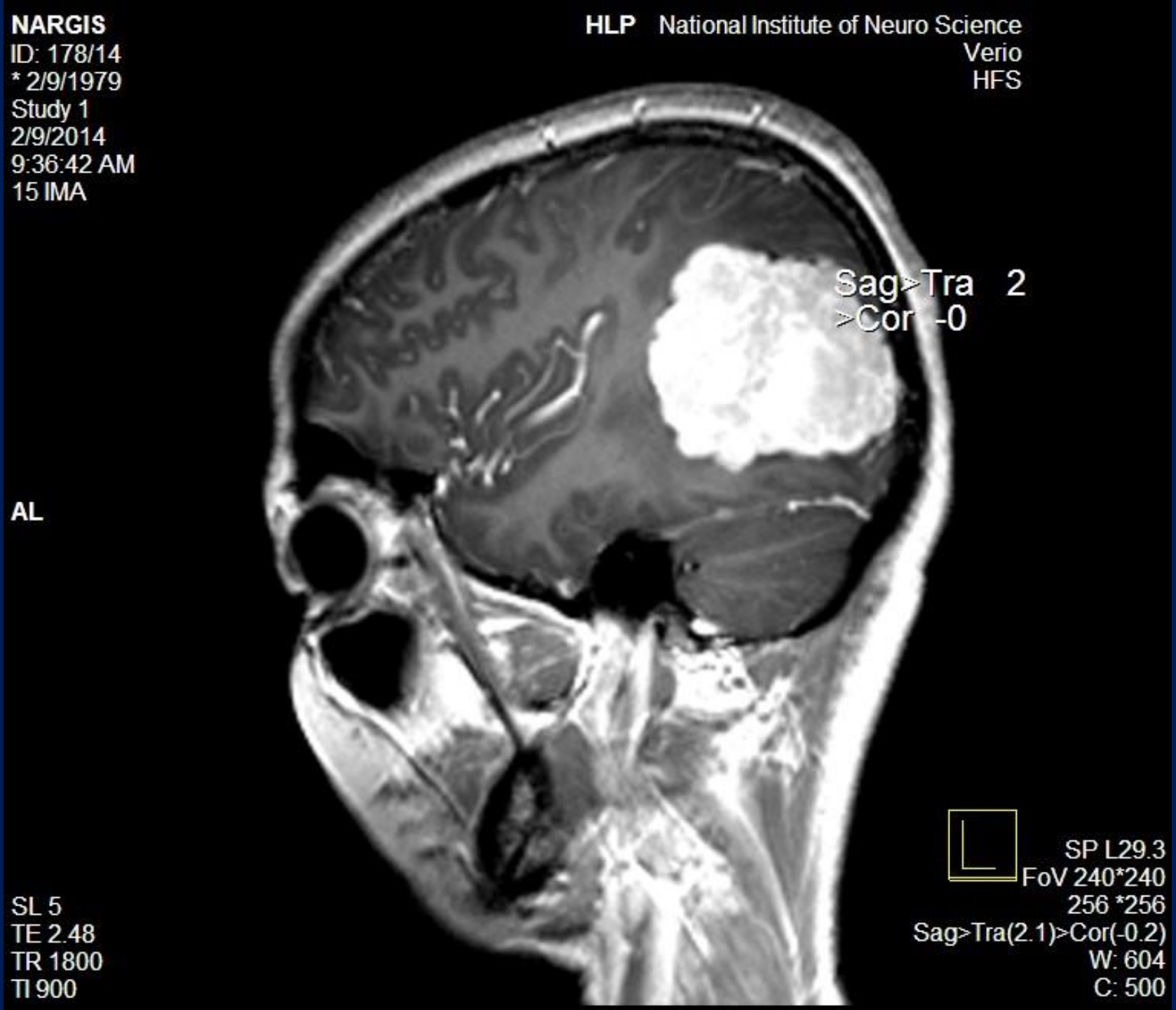
NARGIS
ID: 178/14
* 2/9/1979
Study 1
2/9/2014
9:36:42 AM
15 IMA
HLP National Institute of Neuro Science
Verio
HFS
Sag>Tra 2
>Cor -0
AL
SP L29.3
FoV 240*240
256 *256
Sag>Tra(2.1)>Cor(-0.2)
W: 604
C: 500
SL 5
TE 2.48
TR 1800
TI 900

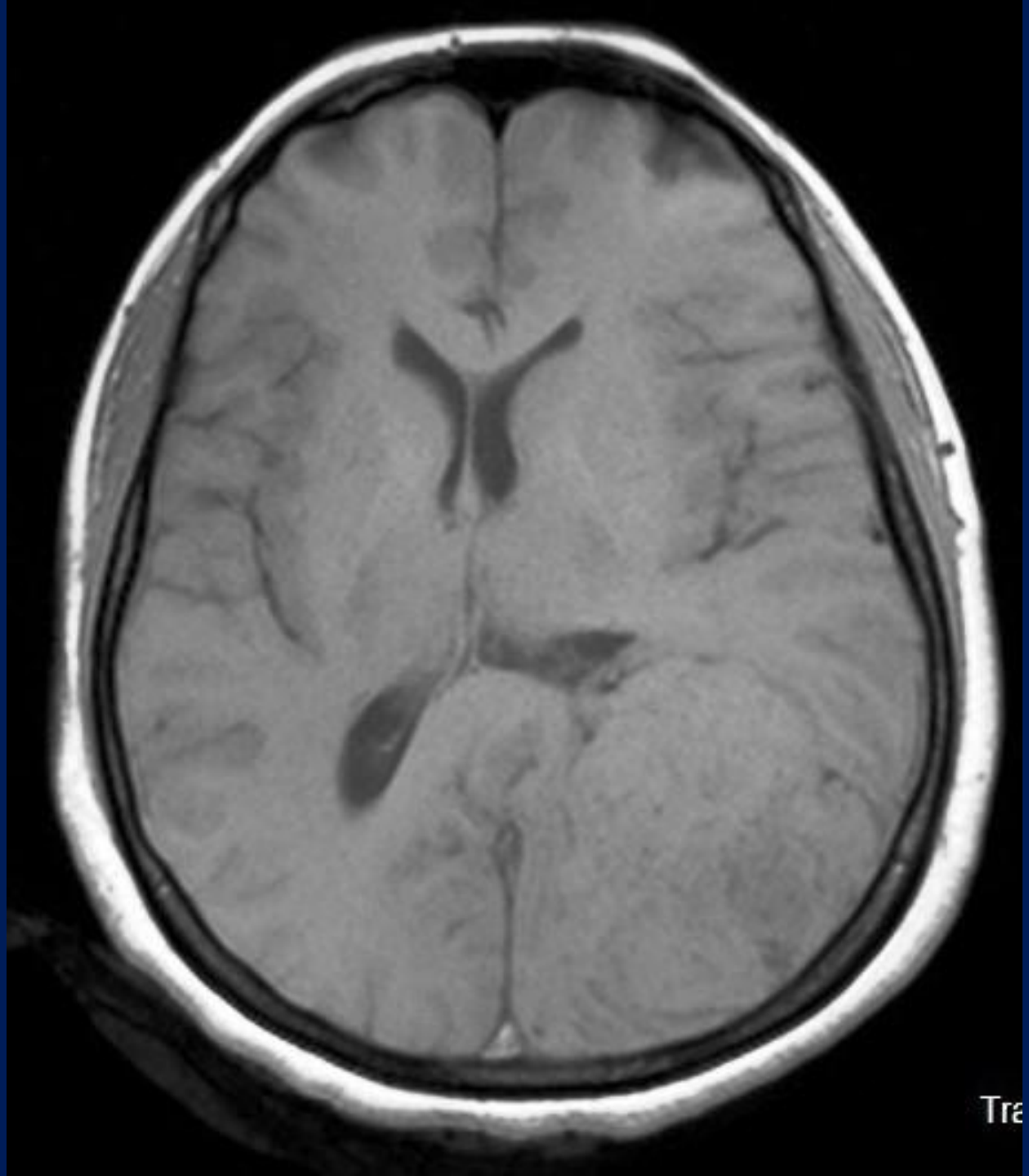
Tra

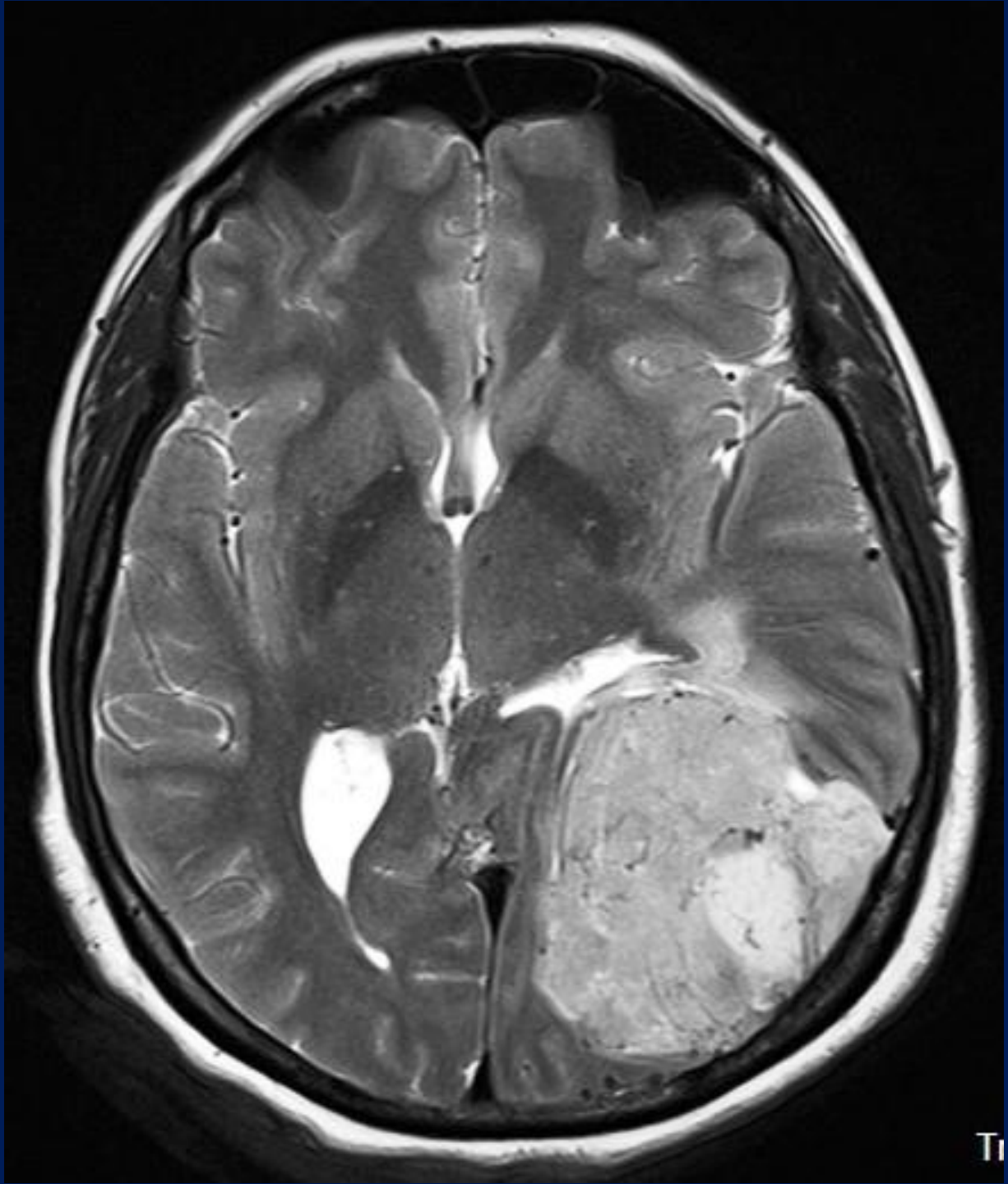
T

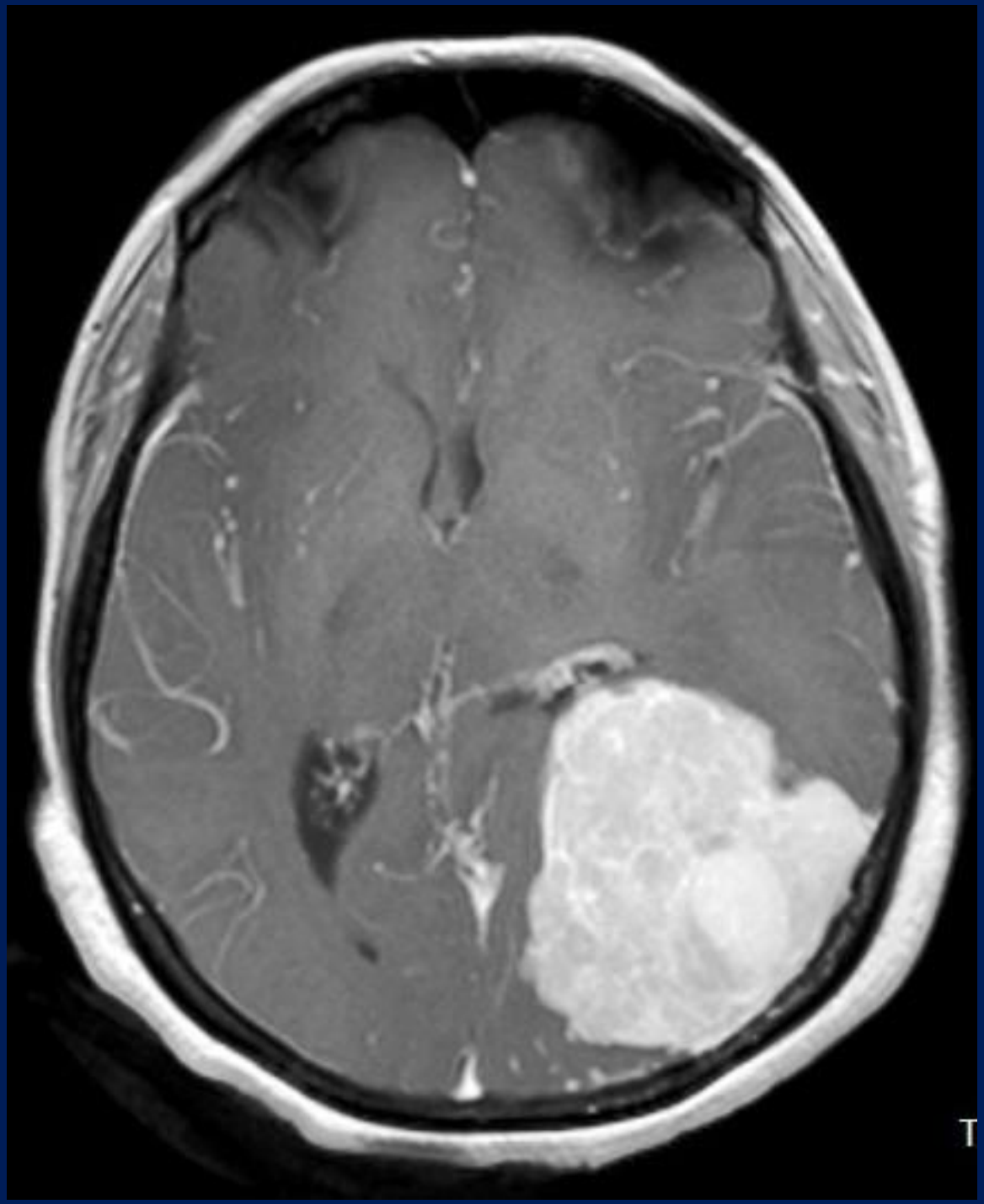
T

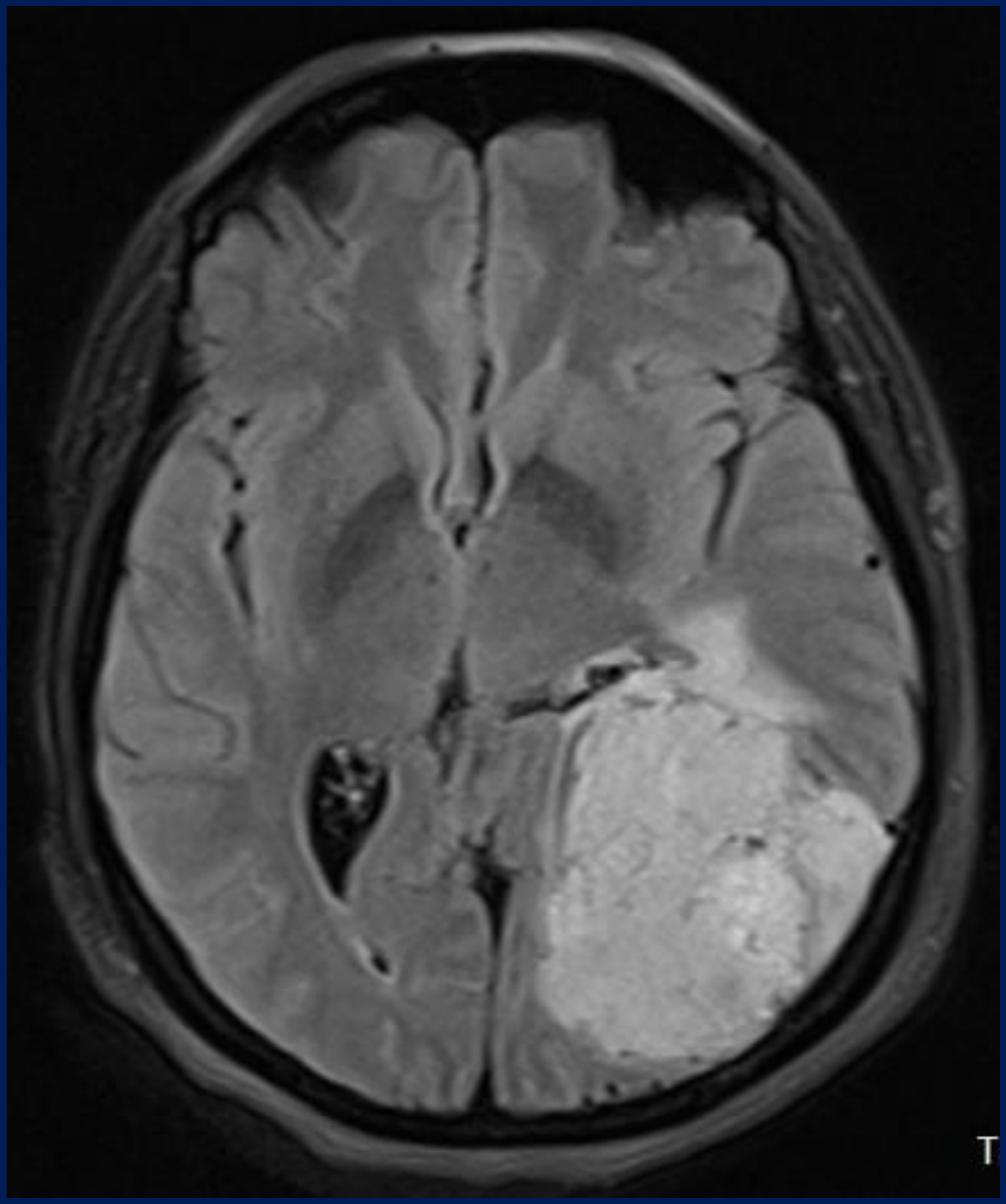
T

- MR perfusion and **MRS** helpful for differentiating neoplastic vs non-neoplastic lesion and tumor grading.

Infection

- Contrast enhanced MRI is essential.

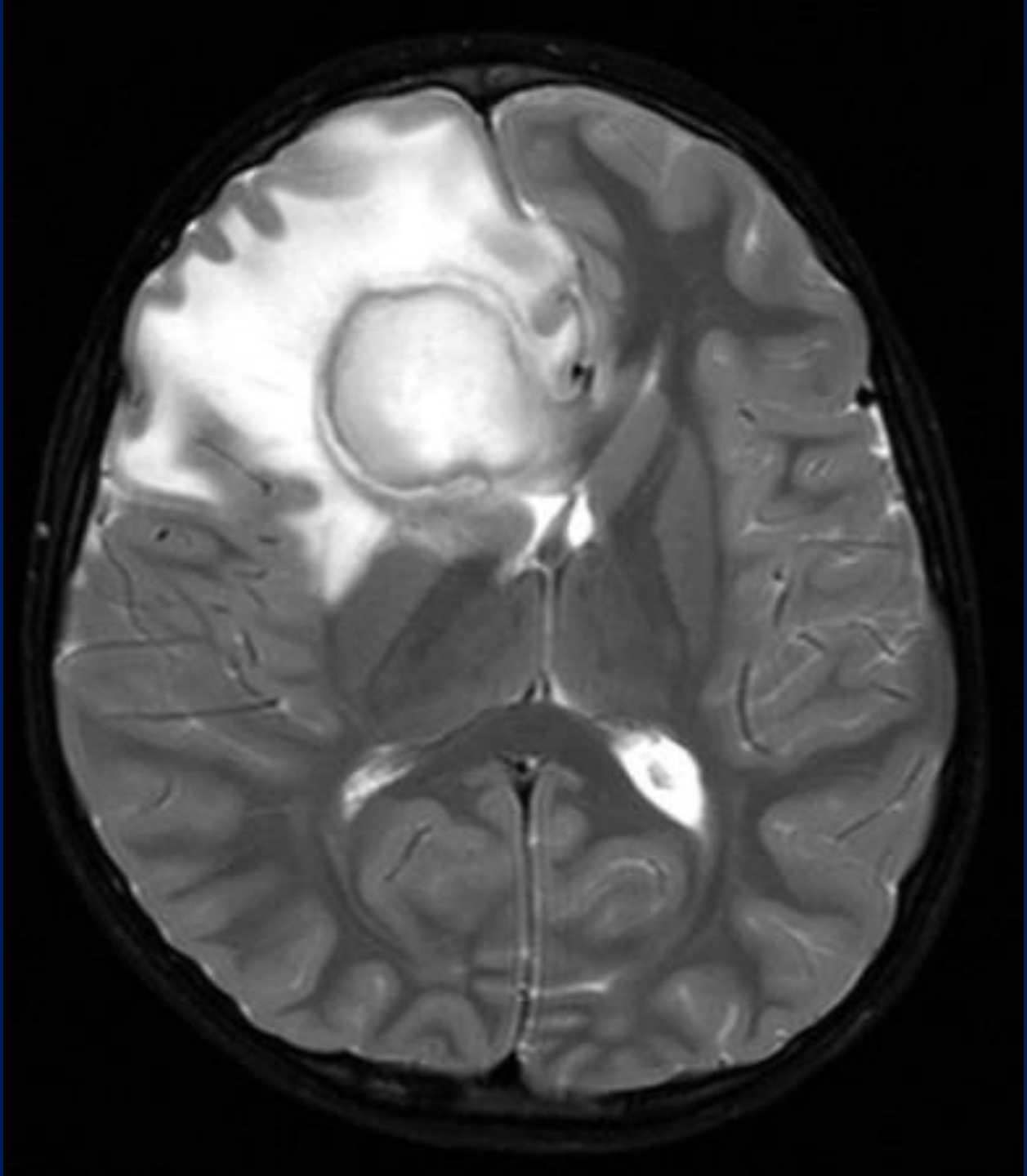

Epilepsy

- Routine imaging the area of focus in epilepsy is temporal lobe and hippocampus.
- FLAIR shows epileptogenic foci in cortex and signal abnormalities in mesial temporal sclerosis.

Hippocampus imaging

- Medium T1 inversion recovery shows cortical dyspasia and migrational abnormalities.

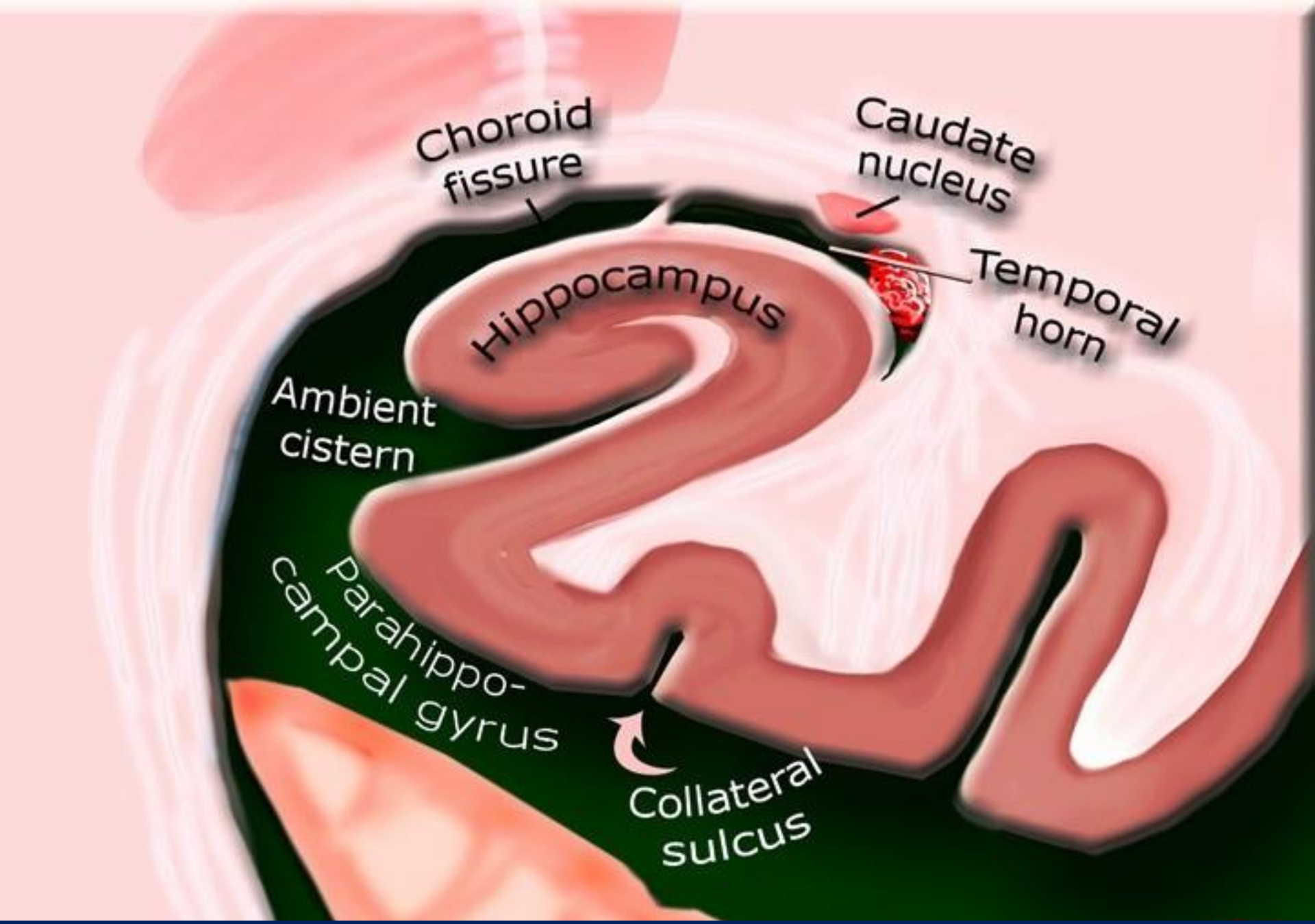

- coronal illustration of the area of the hippocampus.

hippo-
campus

- Coronal T2 Left hippocampal atrophy

CP angle lesion

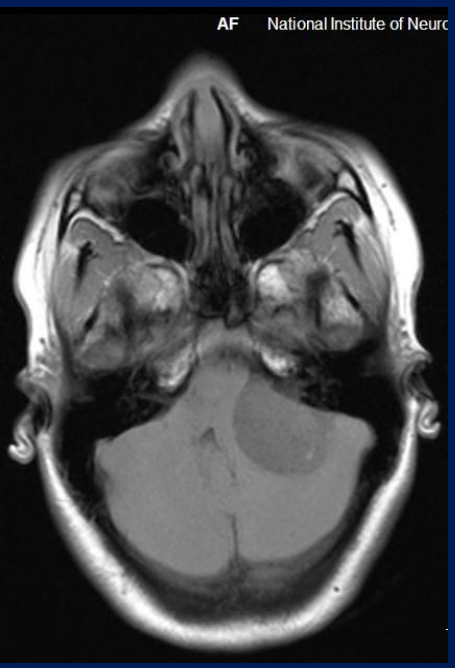

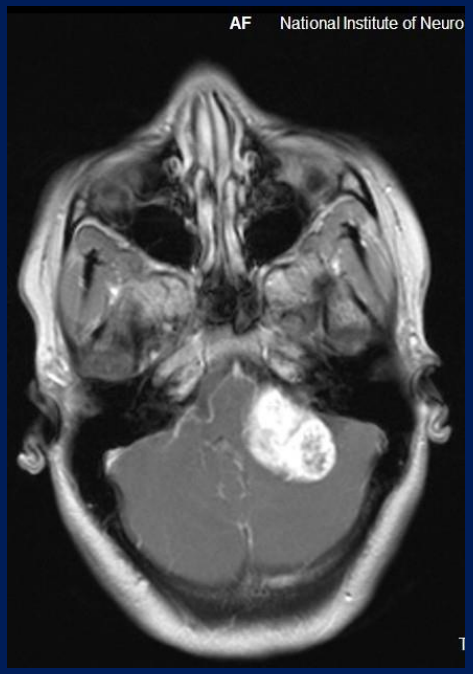

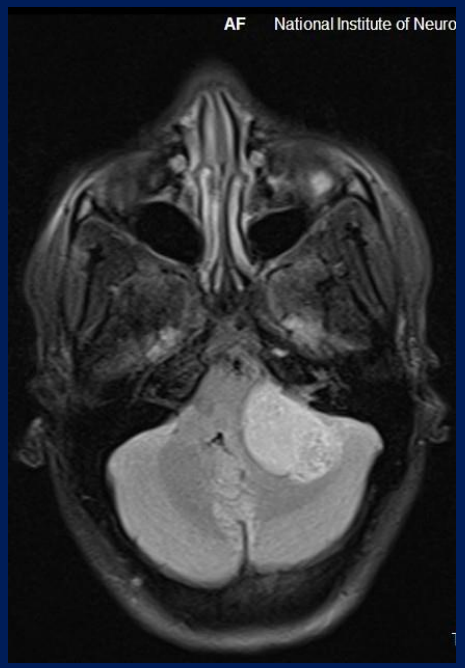

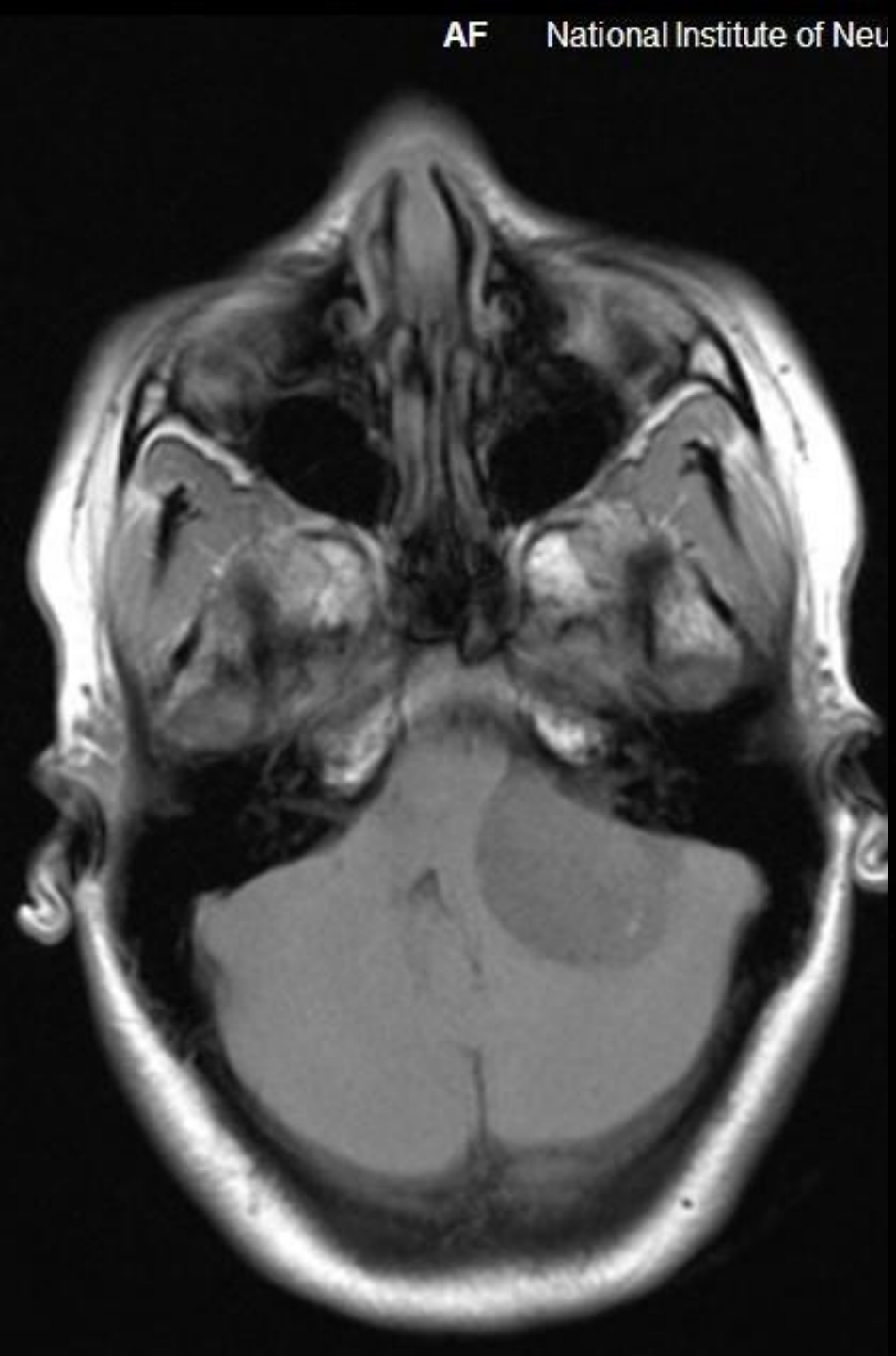
AF
National Institute of Neu

AF
National Institute of Neuro

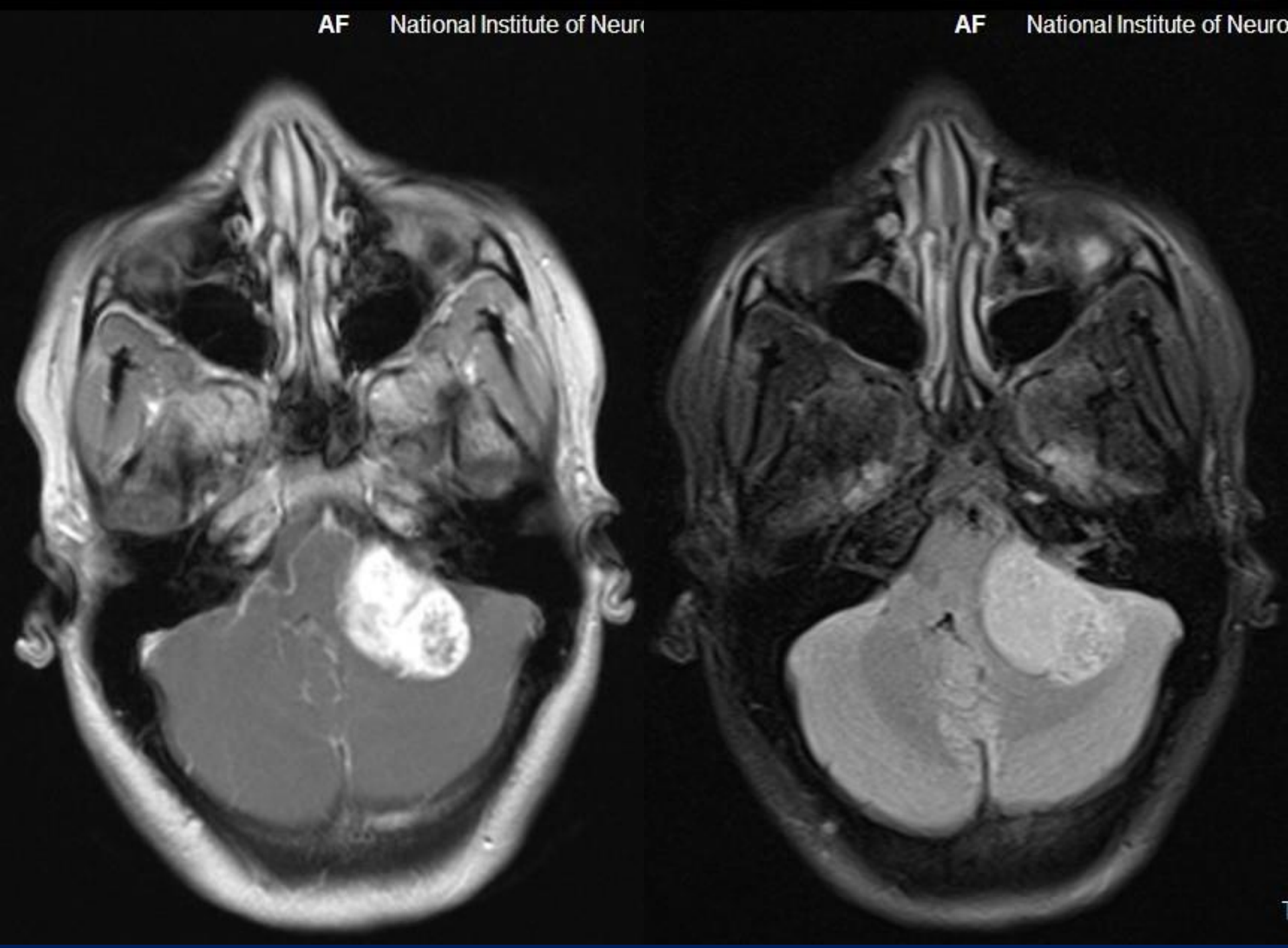
AF National Institute of Neur
AF National Institute of Neuro

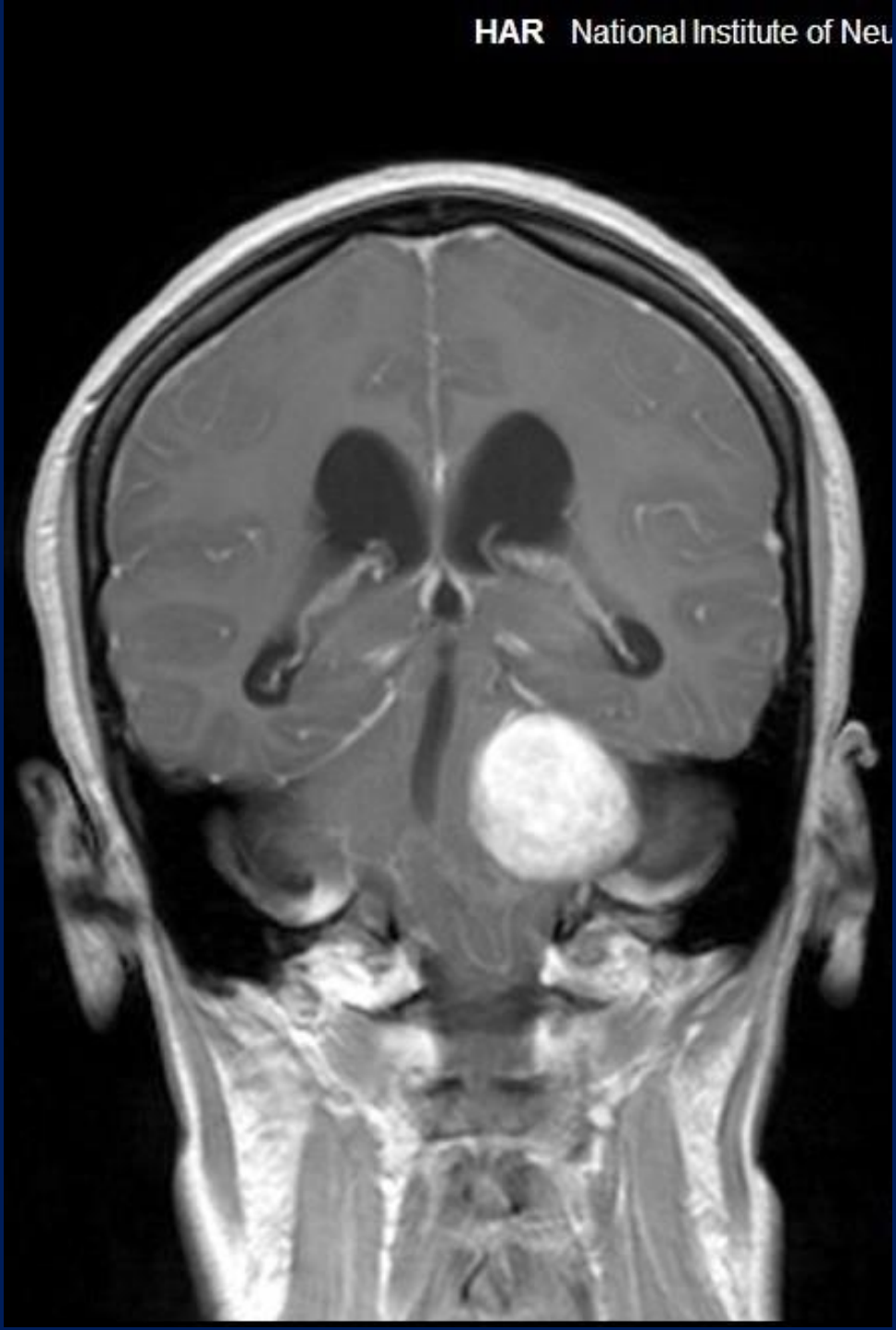
HAR National Institute of Neu

Demyelinating lesions

- T2WI are mainstay for demyelinating lesions .
- FLAIR images show lesions near ventricular margin.
- Enhancing demyelinating lesions are usually active.

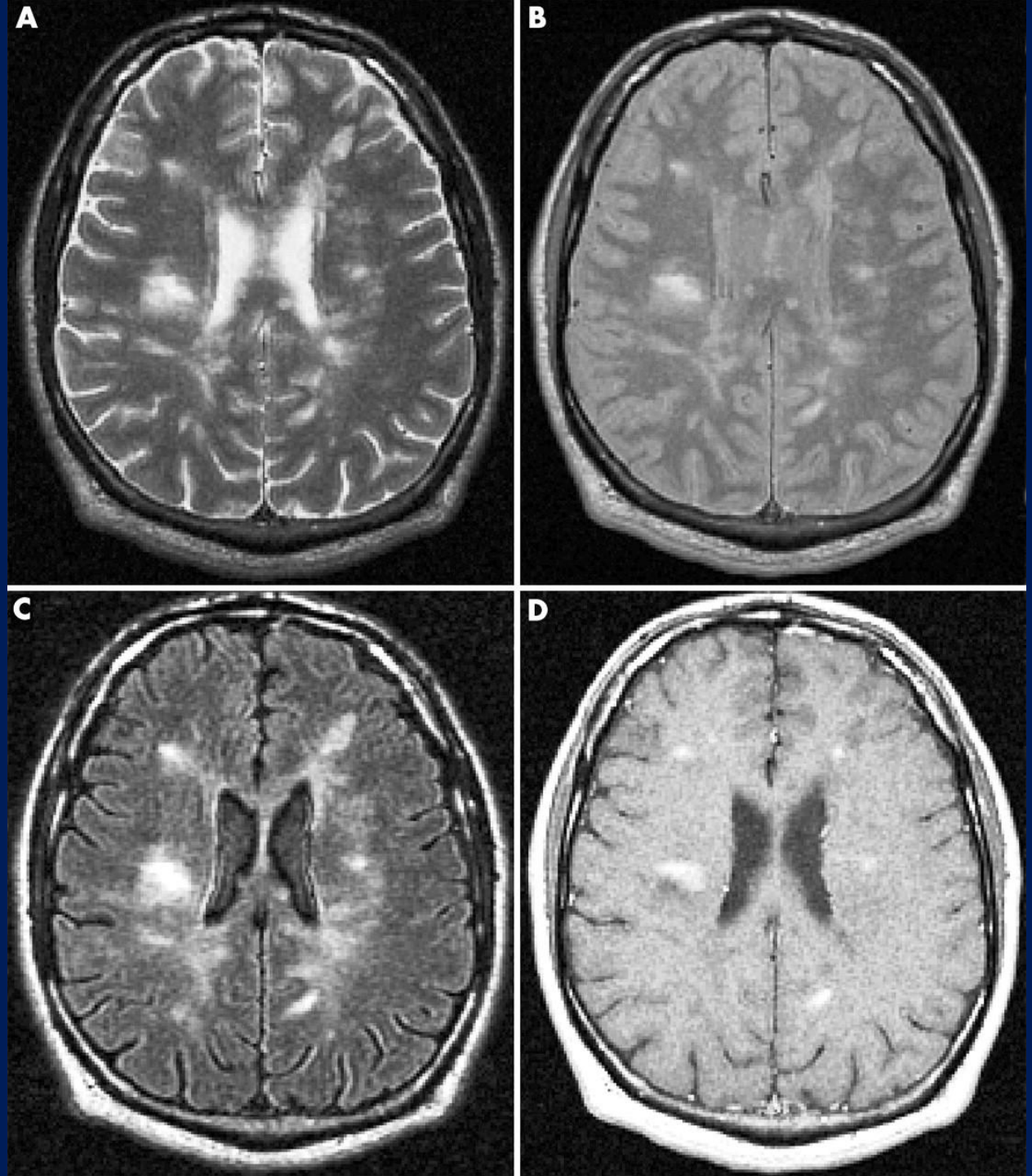
A
B
C
D

Axial magnetic resonance imaging (MRI) of a 30 year old man with relapsing remitting multiple sclerosis (MS) showing multiple periventricular lesions: (A) T2 weighted image; (B) proton density (PD) weighted image; (C) fluid attenuated inversion recovery (FLAIR) image; (D) T1 weighted image following administration of gadolinium (Gd) demonstrating enhancing lesions.

XXXX

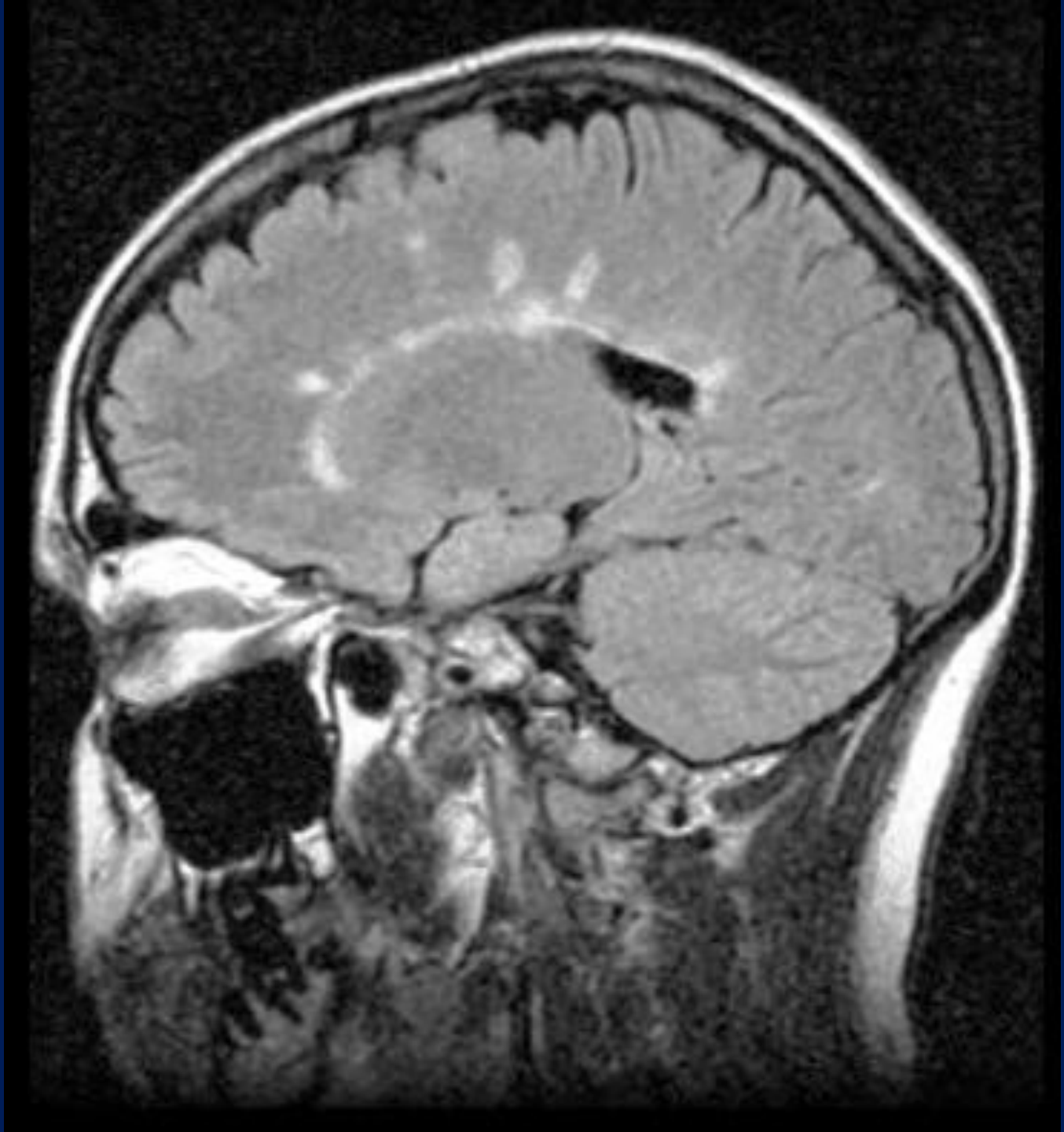

- Acute disseminated encephalomyelitis

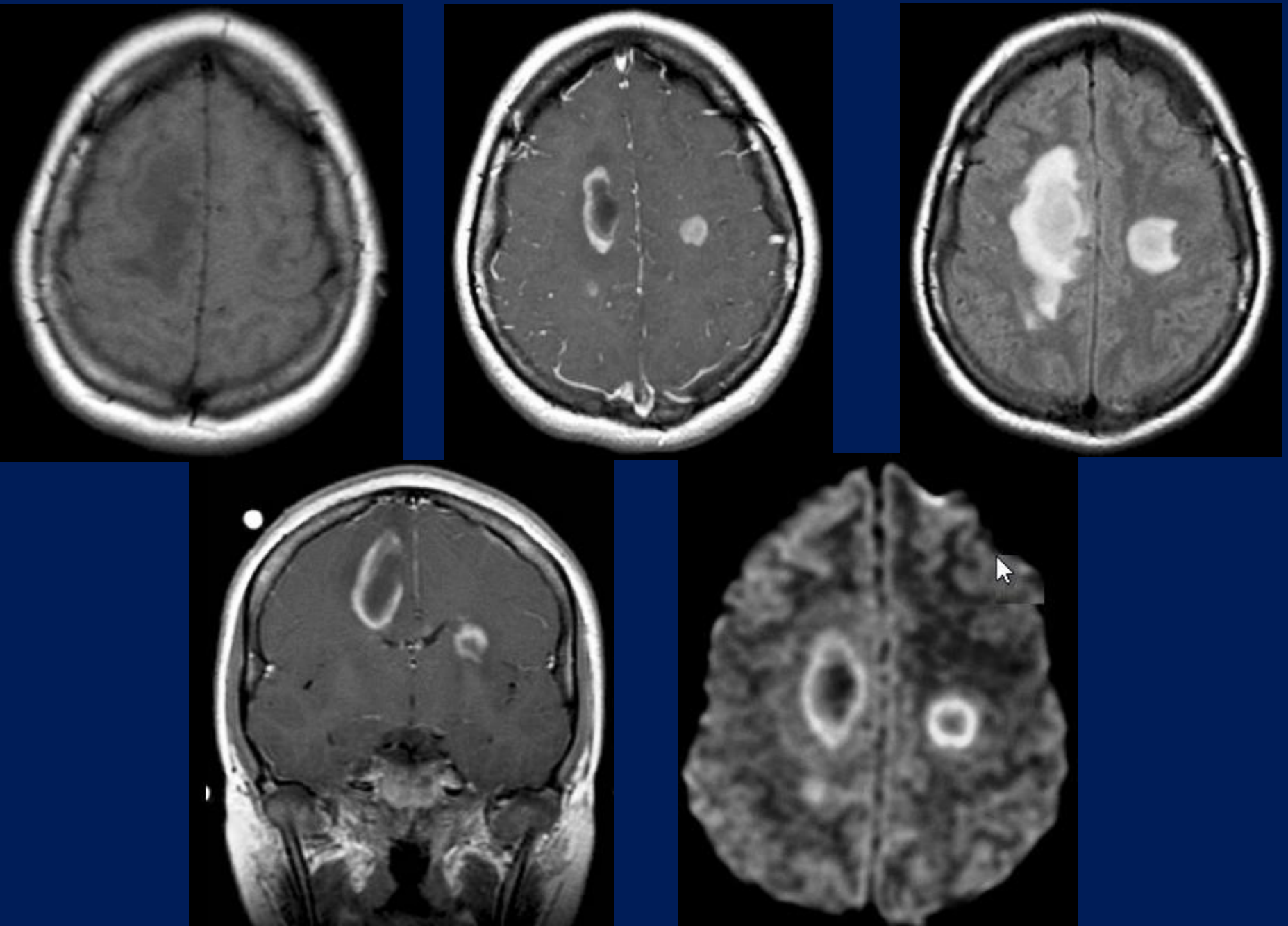

Trauma

- Gradient hemo and T1WI are important in showing acute bleed.
- MRI useful in diffuse axonal injury..

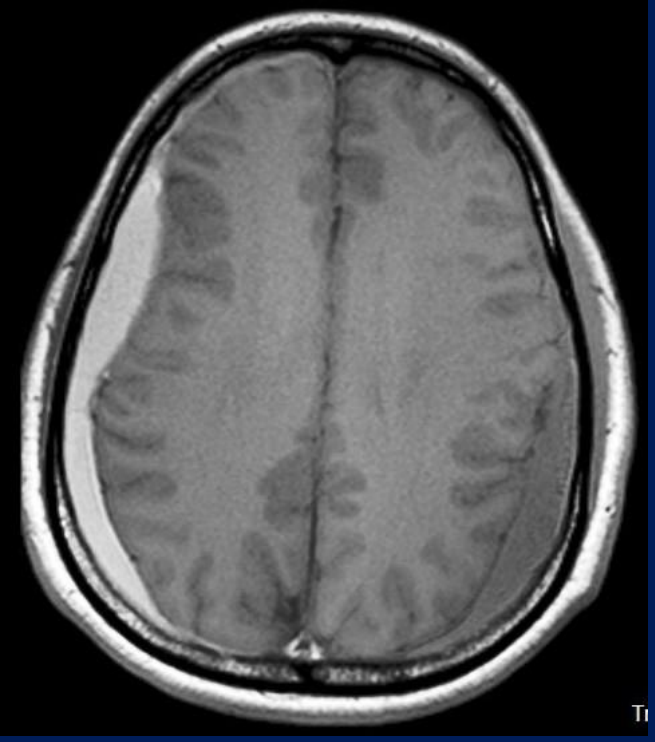
Tı

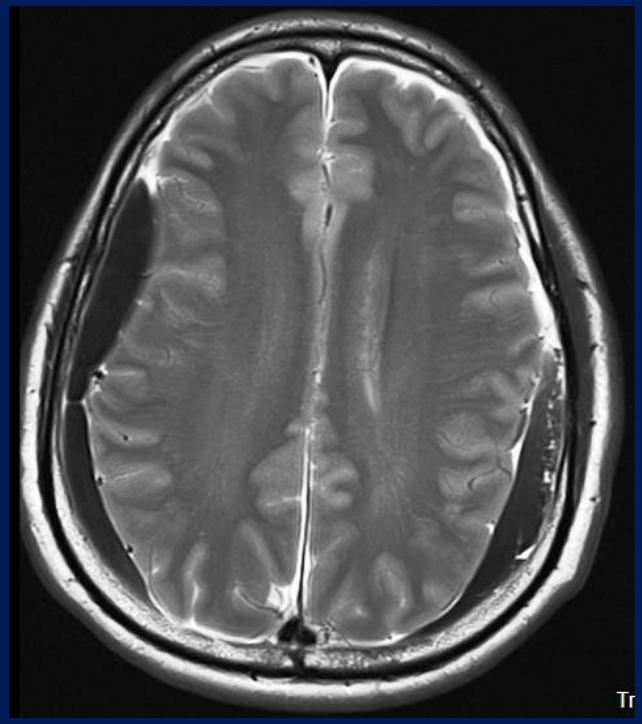
Tr

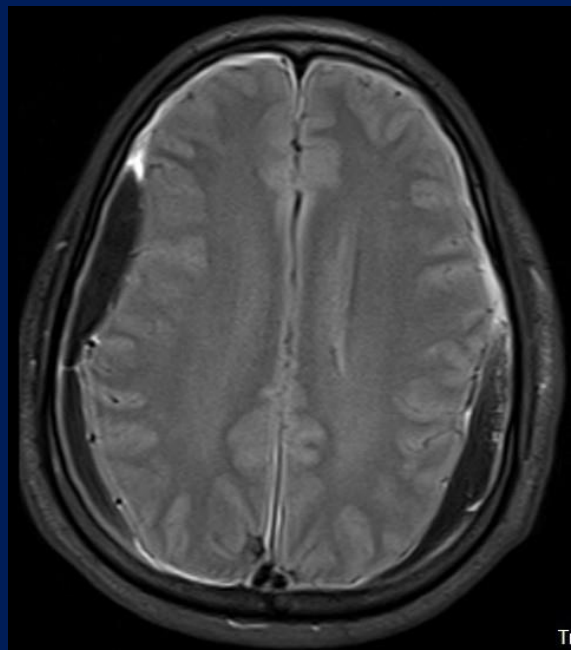

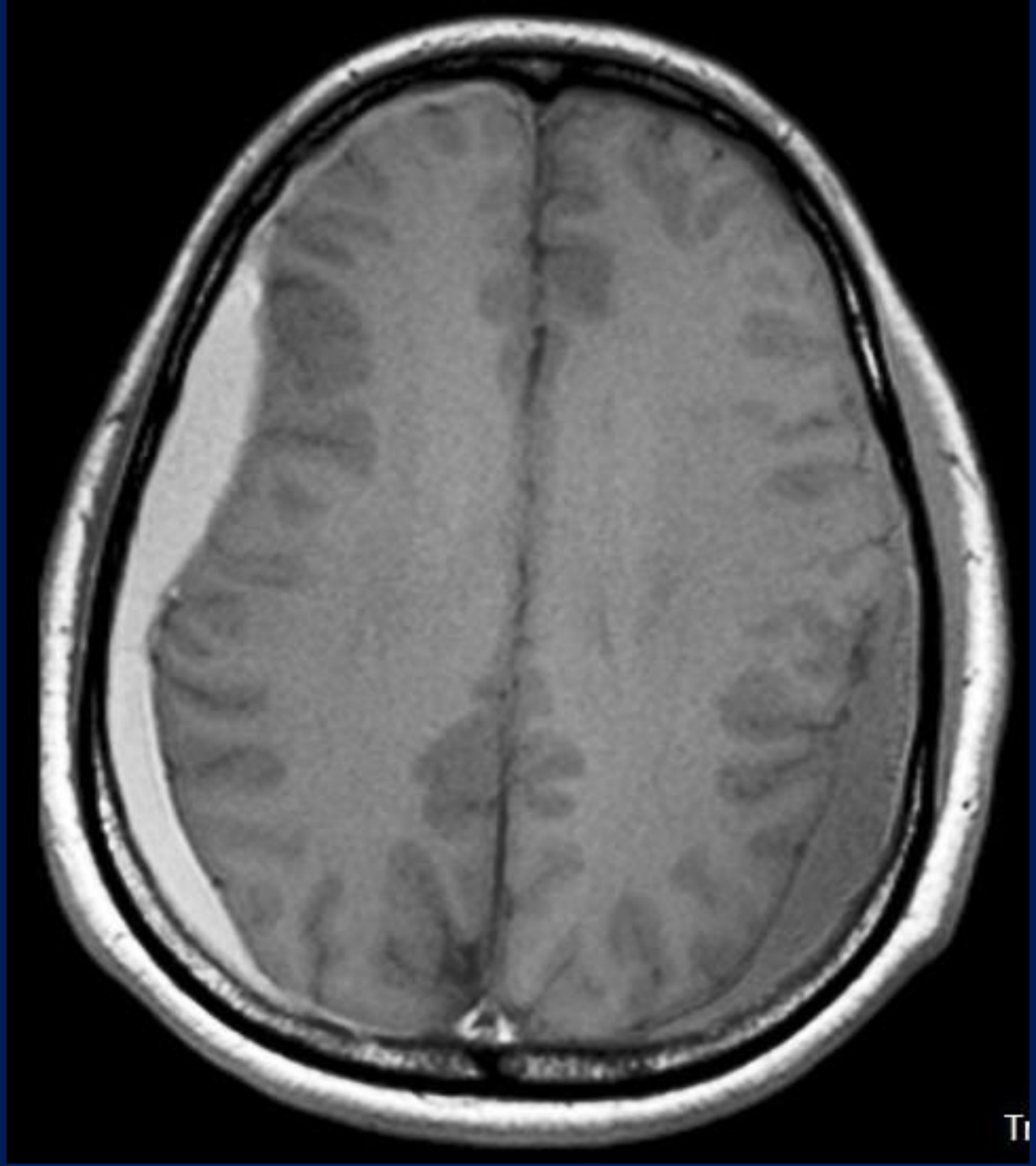
T1

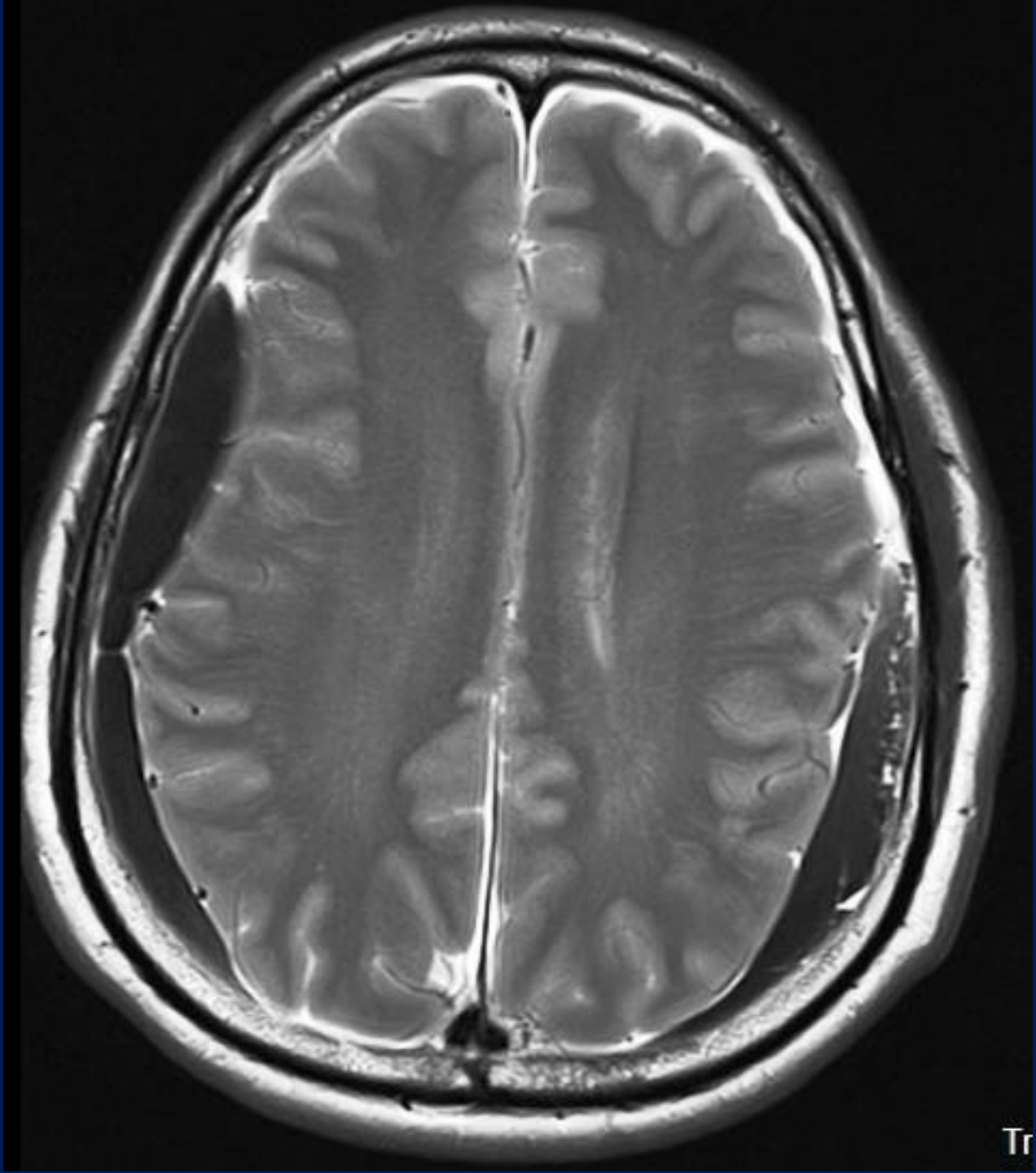
Tr

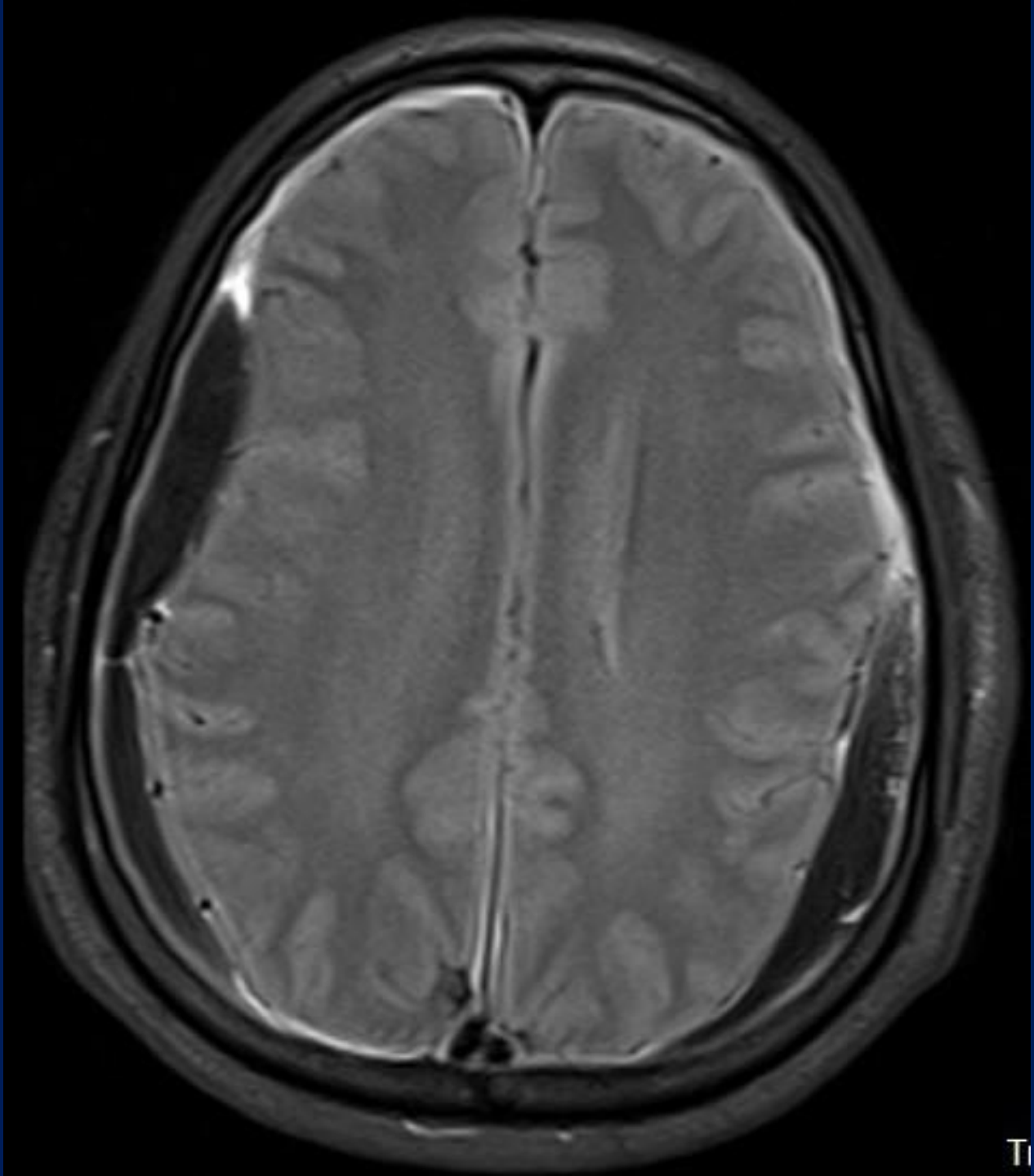
T

Spine imaging

- Common sequences are T1WI, T2WI axial and sagittal images .
- STIR done in vertebral focal lesions, trauma and marrow lesions.

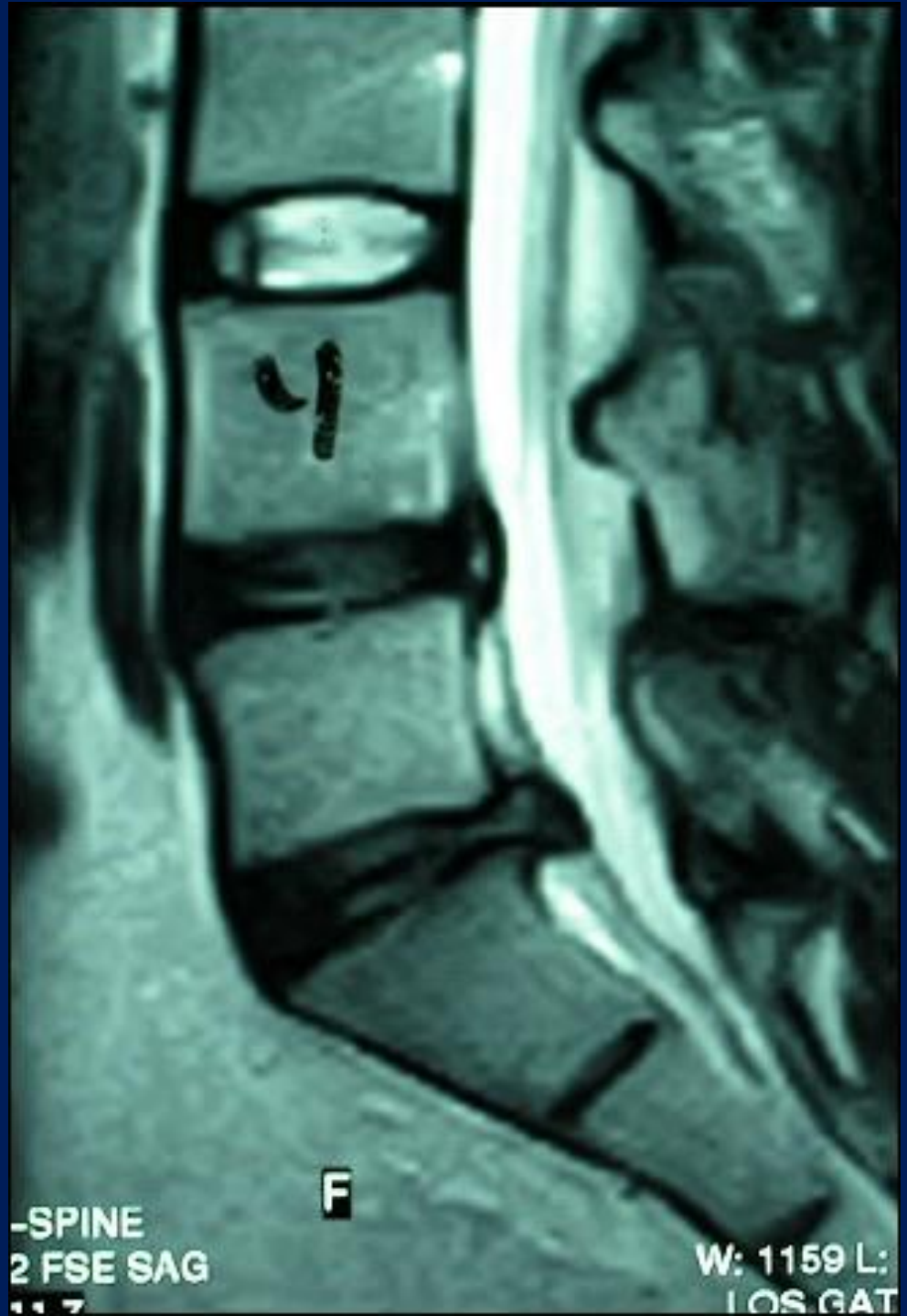
F
-SPINE
2 FSE SAG
W: 1159 L:

Ex: 18037
Sag T2 - BOT
Se: 4/9
Im: 6/11
Sag: R3.1
512 x 512
Mag: 2.9x
Mulla Qureshabanu
056Y F 18037-2011
Acc:
2011 Oct 25
17:34:55
A
P
ET: 27
TR: 3140.0
TE: 87.6
8CTL345
3.0thk/0.5sp
W:10527 L:5215
I
DFOV: 13.8 x 13.8cm

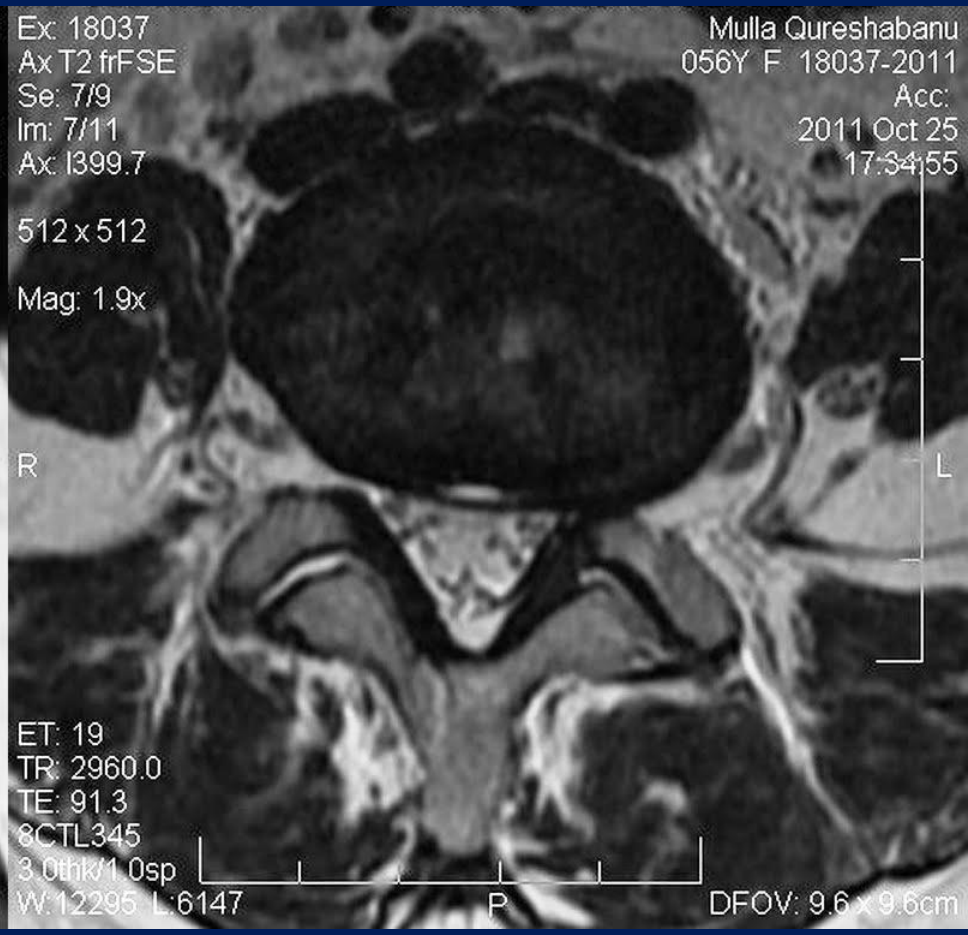
Ex: 18037
Ax T2 frFSE
Se: 7/9
Im: 7/11
Ax: I399.7
512 x 512
Mag: 1.9x
Mulla Qureshabanu
056Y F 18037-2011
Acc:
2011 Oct 25
17:34:55
R
L
ET: 19
TR: 2960.0
TE: 91.3
8CTL345
3.0thk/1.0sp
W:12295 L:6147
P
DFOV: 9.6 x 9.6cm

1091
494
-103
L4/5 disc prolapse

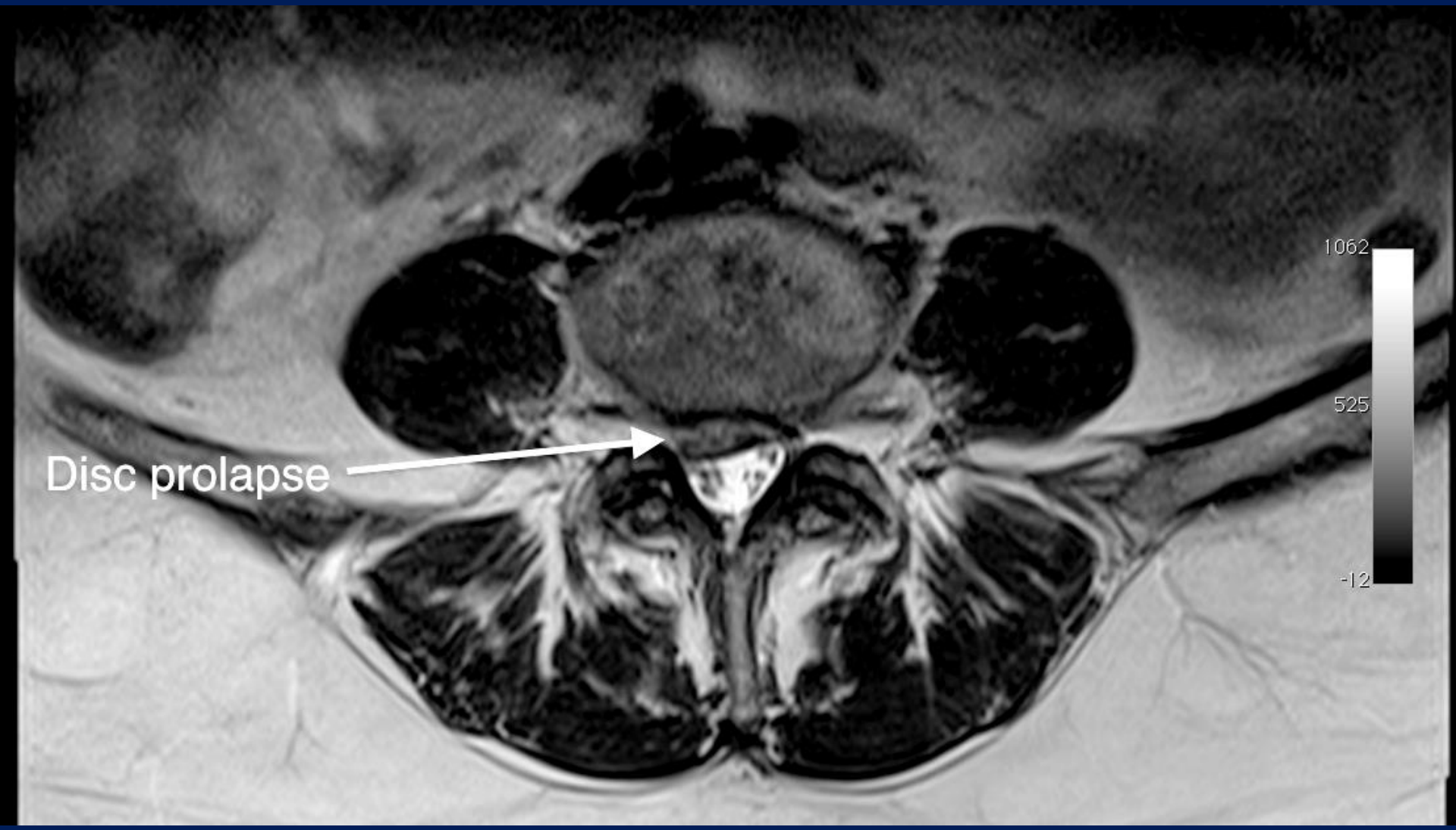
Disc prolapse
1062
525
-12

TAKE HOME MESSAGE

- MRI is an essential tool in Neuroimaging.
- MRI contrast (Gadolinium) may cause Nephrogenic systemic fibrosis (NSF) in patients with severe renal disease & hepatorenal syndrome.
- MRI to be avoided in 1st trimester of pregnancy . Never with Contrast.

- The more the clinical history/ findings provided – the more standard & helpful will be the reporting.