A 17-YEARS-OLD GIRL WITH RIGHT SIDED WEAKNESS….

Presented by

Dr. HUMAYRA JESMIN
IMO
Medicine Dept.
Dhaka Medical College Hospital

Particulars of the patient

Name : Miss J.
Age : 17 years
Address : Daudkandi, Comilla.
Religion : Islam
Marital status : Unmarried
Occupation : Student
Date of admission : 04-01-2014
Date of examination : 04-01-2014

Chief complaints

1. Headache with right sided weakness for 1 day.
2. Altered level of consciousness for 1 day
3. Nasal and per vaginal bleeding for 3 days.
4. Low grade fever for 3 months .

History of present illness

The parent stated that the girl was reasonably well 3 months back. Then she developed fever which was initially low grade, irregular, but not associated with chills and rigor. There was neither evening rise of temperature nor drenching sweat. The fever was not accompanied with sore throat, urinary complaints or abdominal discomfort and usually subsided by paracetamol. Recently for the last 3 days, it was high grade, continued in nature, the highest recorded temperature was 104°F, associated with chills and rigor, and did not subside by antipyretics.

Three days back, she developed multiple non-itchy, reddish spots of various size and shape over right side of her chest, right leg and hand. At the same time, she had several episodes of bleeding from nose, mild to moderate in amount, and it was not precipitated by any trauma. She also had moderate PV bleeding as well. Two days after the spike of fever, she developed headache and became delirious with changing behavioural pattern followed by right sided weakness that made her incapable to continue regular activities . The headache was of sudden onset, severe in nature, global in character, not associated with vomiting, blurring of vision or convulsion.

On query parent mentioned that she had history of multiple joint pain without any swelling and movement restriction. The girl lost significant weight during her present illness.

There was no history of haematuria, haemoptysis, haematemesis, melaena or haematochezia and no abdominal pain, alteration of bowel habit, oral ulcer and photosensitivity. She had no past history of jaundice and contact with TB patient. There was also no history of exposure.

History of past illness

She had no previous history of such type of illness.

Family history

None of her family members suffered from such type of illness and there is no history of consanguinity of marriage between her parents.

Drug history

Paracetamol for fever and joint pain.

No history of taking aspirin, NSAID, anticoagulant and steroid.

Antibiotics possibly irregularly taken but name of the drug is not known.

Socioeconomic history

Below average

Travelling history

No history of travel to hill tracts

Immunization history

She was immunized as per EPI schedule.

Menstrual History

- Flow : Average
- Duration : 3-4 days
- Cycle : Regular
- **L.M.P : 05.12.2013**

PHYSICAL EXAMINATION

General examination

Appearance	Very ill looking
Body built	Average
Cooperation	Unable to communicate
Nutrition	Average
Decubitus	Lying
Anaemia	Moderate
Jaundice	Absent
Cyanosis	Absent

General examination

Clubbing	Absent
Koilonychia	Absent
Leukonychia	Absent
Oedema	Absent
Bony tenderness	Not elicited
Pulse	90 beats/min
Blood pressure	100/60 mm Hg
Respiratory rate	24 breaths/min

General examination

Temperature	102° F
Neck vein	Not engorged
Thyroid gland	Not enlarged
Dehydration	Absent
Body hair distribution	Normal

➢Lymph node:

- Bilateral posterior cervical and left supraclavicular lymph nodes were palpable. They were of variable size, discreet, the largest one measuring 4 cm X 2 cm, firm in consistency, tender, not fixed with the underlying structures or overlying skin, no discharging sinus, and local temperature over the node was little bit hot.

➢Skin condition:

- There were pleomorphic purpuric spots over upper right chest and anterior aspect of right leg .
- Ecchymoses over medial aspect of right elbow.
- Subconjunctival haemorrhage in left eye.

Systemic Examination

Nervous system

Parameters	On Admission
Higher psychic function	Disoriented
Cranial nerves	Could not be evaluated
Sensory function	Could not be evaluated

Motor function	On Admission	
	Right limbs	Left limbs
Muscle tone	Hypertonic	Normal
Muscle power	2/5(approx)	5/5(approx)
Biceps jerks	Exaggerated	Normal
Triceps jerks	Exaggerated	Normal
Knee jerks	Exaggerated	Normal
Ankle jerks	Exaggerated	Normal
Plantar response	Extensor	Flexor

Signs of meningeal irritation : Absent

GCS : E4V4M5

Pupils : Symmetrical, rounded, regular, reacting to light.

Fundoscopy : Bilateral papilloedema and flame shaped haemorrhage in lower nasal field of left eye.

➢Alimentary system

- No gum bleeding or oral ulceration.
- Liver: Palpable, 4 cm from right subcostal margin, firm in consistency, tender, with smooth surface and regular margin, upper border of liver dullness in right 5th intercostal space along with midclavicular line.
- Spleen: Not palpable.
- No fluid thrill.
- Shifting dullness : Absent.

➢Cardiovascular system

- Apex beat: left 5th intercostal space just medial to the midclavicular line.
- Heart sounds: Normal. No murmur or added sound

➢Respiratory system

- Chest movement: normal
- Trachea is central in position.
- Breath sound: vesicular. No other added sound .

➢Locomotor system

- No evidence of arthritis.

Salient features

A 17-year-old unmarried girl presented with 3 days high-grade continued fever with chills and rigor on top of low-grade irregular fever and arthralgia involving large joints for 3 months, skin rash, subconjunctival haemorrhage and episodes of spontaneous, nasal, as well as, PV bleeding for 3 days. Two days later she developed sudden severe headache, alteration of consciousness followed by right sided weakness. She had no history of trauma, convulsion, abdominal pain, alteration of bowel habit, alopecia, oral ulcer, photosensitivity, yellowish discoloration of sclera or urine, previous bleeding manifestations, contact with tuberculosis, and travel to hill tracts or any history of exposure.

Physical examination revealed toxic appearance with disorientation, moderate anaemia, bilateral posterior cervical and left supraclavicular tender lymphadenopathy, impalpable, non-tender, pleomorphic purpura over upper right chest and right leg and ecchymoses over right elbow. Her pulse was 90/min, regular, B.P. 100/60 mmHg, temperature 102° F, GCS E4V4M5, there were bilateral papillodema and retinal haemorrhage in left eye, right sided UMN type of hemiparesis, and tender hepatomegaly, 4 cm from right subcostal margin. There were no signs of meningeal irritation, splenomegaly, murmur, and evidence of arthritis.

Provisional diagnosis

Septicemia with acute stroke with right sided hemiparesis.

Differential diagnosis

1. Acute leukaemia with stroke with right sided hemiparesis
2. Systemic lupus erythematosus (SLE) with Vasculitis
3. Tuberculosis with tuberculoma in brain
4. Lymphoma

Investigations

Blood counts

Parameter	4/1/2014	5/1/2014	8/1/2014
HB% (gm/dl)	9.5	7	10.1
ESR	110	84	41
HCT%	22%	26.2%	37%
Total platelet count	<10000	10000	13000
TC of WBC cmm	6500	3500	7600
N	84%	80%	76.80%
L	7%	16%	14.80%
M	3%	2%	7.90%
E	1%	2%	0.50%
Atypical looking mononuclear cell	5%	nil	nil
MCV(ft)	80	80.1	97

PBF	Finding
On 04.01.14	Bicytopenia with few atypical looking mononuclear cells.
On 05.01.14	Pancytopenia

Reticulocyte count : 5%

BT : 4 min. 15 sec

CT : 6 min

Bone marrow (08.01.14):

Hyper active marrow.

Increased cellularity in all three cell lines.

- SGPT : 40 U/L
- LDH : 296 U/L
- CRP : 4.02 mg/L (Risk high >3 mg/L)
- Serum Creatinine : 0.50 mg/dl
- Serum Electrolytes : Na-141 mmol/L,K-3.8 mmol/L,Cl- 111 mmol/L
- MT : 4-5 mm

- ICT for malaria : Negative
- ICT for Kala-azar : Negative
- Triple Antigen : Non significant titre
- ANA : Negative for ANA
- Anti ds DNA : Negative
- Anti phospholipid Ab : Negative

- Routine urinalysis :
  - Albumin Trace
  - Pus cell 6-8/HPF
  - RBC 15-20/HPF.
- Urine for C/S (08.01.14) :
  - *E. coli* ($1x10^7$ CFU/ml).
  - Sensitive to Nitrofurantoin, Pivmecillinam.
- Blood C/S :
  - No growth.

Chest X-ray

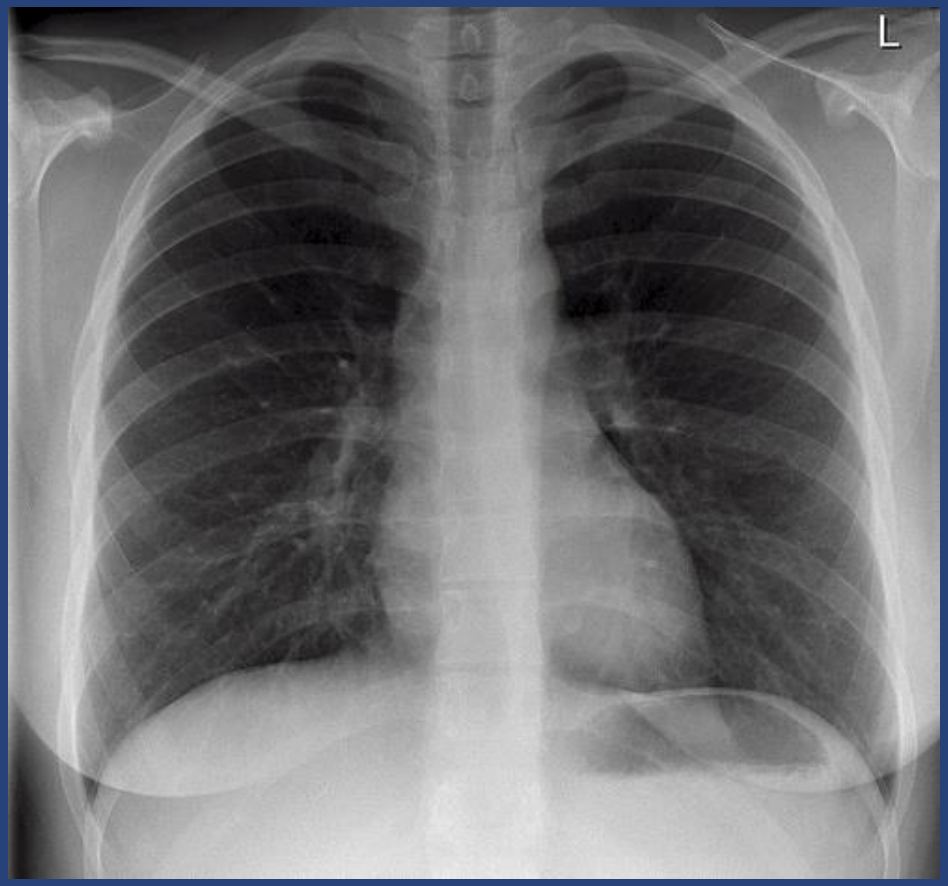

CT scan of head

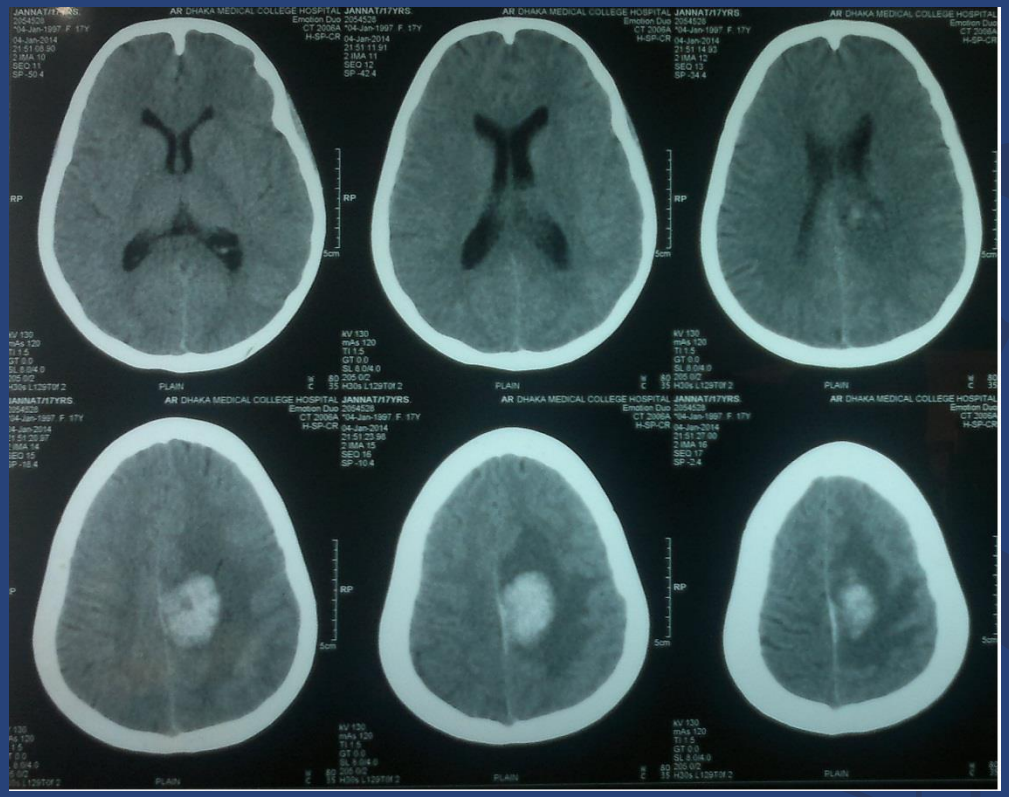

A large intracerebral haematoma occupying parietal region(left)

- **USG of Whole Abdomen(on 05.01.14) :**

  - Mild hepatomegaly .
  - No lymphadenopathy.
  - Normal other findings.

- **Coagulation profile:**

Parameters		9-1-2014
PT	Control	11.8 sec.
	Patient	12 sec.
	INR	1.01
APTT	Control	28 sec.
	Patient	30 sec.
FDP	10 ug/dl (normal<5 ug/dl)	
D-dimer	1.34 mg/l FEU (normal<o.55 mg/l FEU)	

Treatment given

- On admission, the girl was very much toxic, disoriented and anaemic as well,
- Initially she was resuscitated by :

  -IV Fluid

  -IV Hydrocortison

  -IV Ceftriaxone

  -Antipyretics.
- After getting the report of urine c/s

  -IV pivmecillinum was added.

- In the meantime she was given 4 units of FFP and 2 units of fresh whole blood.

FOLLOW UP EXAMINATION

Seven days after admission ,we examined the girl again and found gradual improvement of her general condition.

- Fever was on remission.
- Skin rashes got faded….no further bleeding was seen.
- But her lymph nodes were increasing in size.

Nervous System

Parameters	10-01-2014
Higher psychic function	Intact
Cranial nerves	Intact
Sensory function	All modalities are impaired in right upper and lower limbs

Motor function	10-01-2014	
	Right limbs	Left limbs
Muscle tone	Hypertonic	Normal
Muscle power	3/5	5/5
Knee jerks	Exaggerated	Normal
Ankle jerks	Normal	Normal
Plantar response	Extensor	Flexor
Biceps jerks	Exaggerated	Normal
Triceps jerks	Exaggerated	Normal

- Signs of meningeal irritation : Absent
- GCS : $E4V_5 M_6$
- Pupils : Symmetrical, Rounded, regular, reacting to light
- Fundoscopy : Gradually disc margin of left eye cleared off and retinal haemorrhage disappeared .

Follow up investigations

CBC ē ESR

Parameter	11/1/2014	20/1/2014
HB% (gm/dl)	10.7	15.9
ESR	50	34
HCT%	32.8%	48.1%
Total platelet count	44000↑	133000↑
TC of WBC cmm	8940	6650
N	84.75%	76.20%
L	11.70%	21.40%
M	3.10%	1.20%
E	0.40%	1.20%
Reticulocyte count	3.76%	
MCV(ft)	83.9	83.8

Reticulocyte count(11.01.2014) : 3.76%

PBF :

Date	Findings
11-1-2014	Normocytic anaemia with thrombocytopenia
20-1-2014	Mild thrombocytopenia

Urine R/E :

Parameters	22-1-2014
Color	Straw
Protein	Nil
Pus cells	1-2/HPF
R.B.C	1-2/HPF

Coagulation Profile :

Parameters		22-1-2014
PT	Control	12 sec.
	Patient	12.7 sec.
	INR	1.04
APTT	Control	28 sec.
	Patient	28 sec.
D-dimer		<0.5 µg/ml (normal<0.5 µg/ml)

USG of Whole Abdomen(18.01.14) :

- Spleen is normal in size(8.6 cm) but shows small ill defined SOLs of variable sizes throughout the spleen.
- Mild hepatomegaly .
- Normal other findings.

Diagnosis?

Lymph node (Right supraclavicular) biopsy:

Microscopic : Sections shows **caseation necrosis**

<u>Diagnosis :</u>

Granulomatous inflammation suggestive of **Tuberculosis**

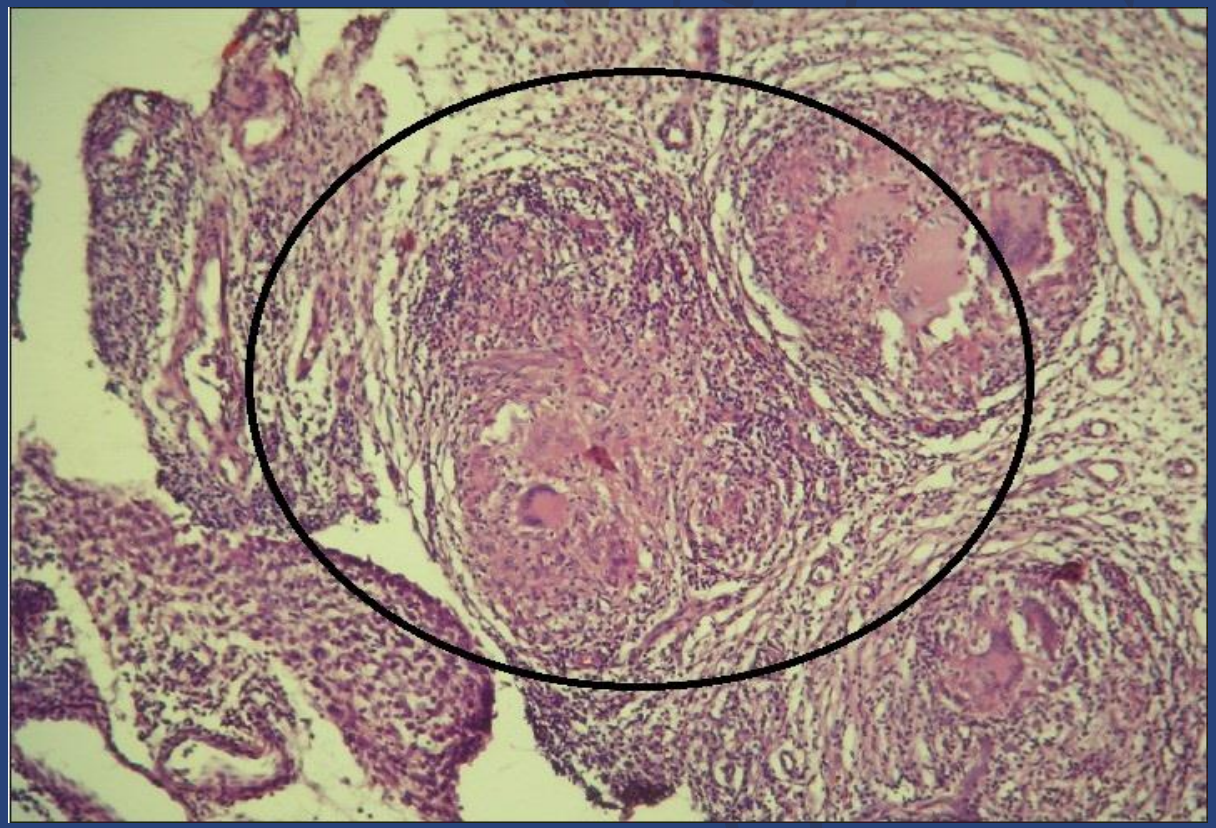

FINAL DIAGNOSIS IS….

TB Lymphadenitis with dissemination with acute severe urinary tract infection with septicemia with intracerebral haemorrhage with DIC.

Thank you all